



ANTERIOR DISLOCATION OF SHOULDER

SHOULDER COMPLEX

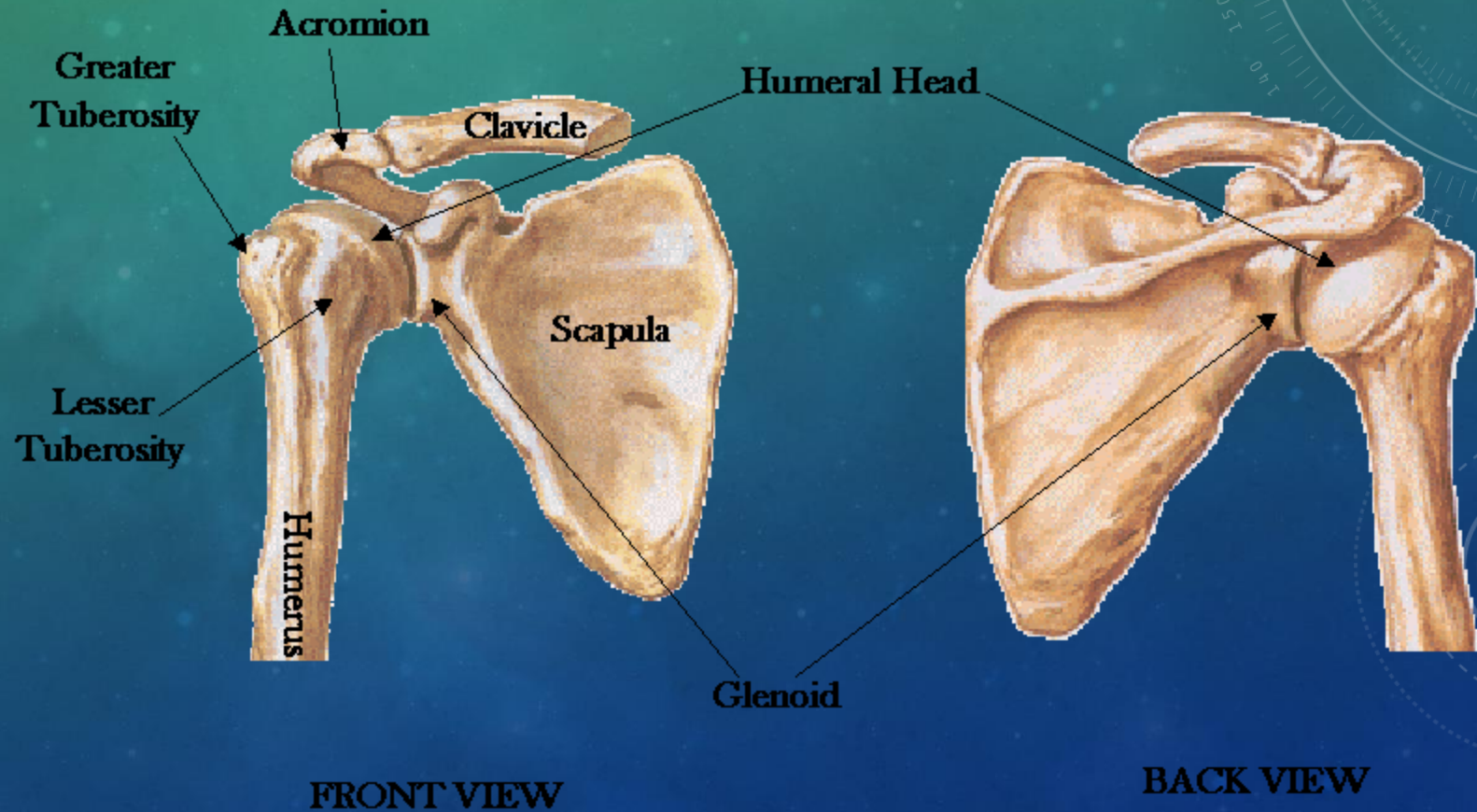
➤ Comprises of 3 Bones, 5 Joints, related muscles and ligaments

Functions:

- Links upper extremity to the trunk
- Provides extensive mobility of arm
- Provides stability and support for skilful and forceful movements of wrist and elbow

OSTEOLOGY

- Humerus
- Scapula
- Clavicle



STABILIZERS OF SHOULDER JOINT

i) STATIC STABILIZERS:

1. Articular anatomy
2. Glenoid Labrum
3. Ligaments
4. Negative intra-articular pressure

ii) DYNAMIC STABILIZERS:

1. Rotator cuff muscles
2. Biceps tendon
3. Periscapular muscles

i) STATIC STABILIZERS

The background features a green-to-blue gradient with faint technical diagrams, including circular gauges with numerical scales and arrows, suggesting a scientific or engineering context.

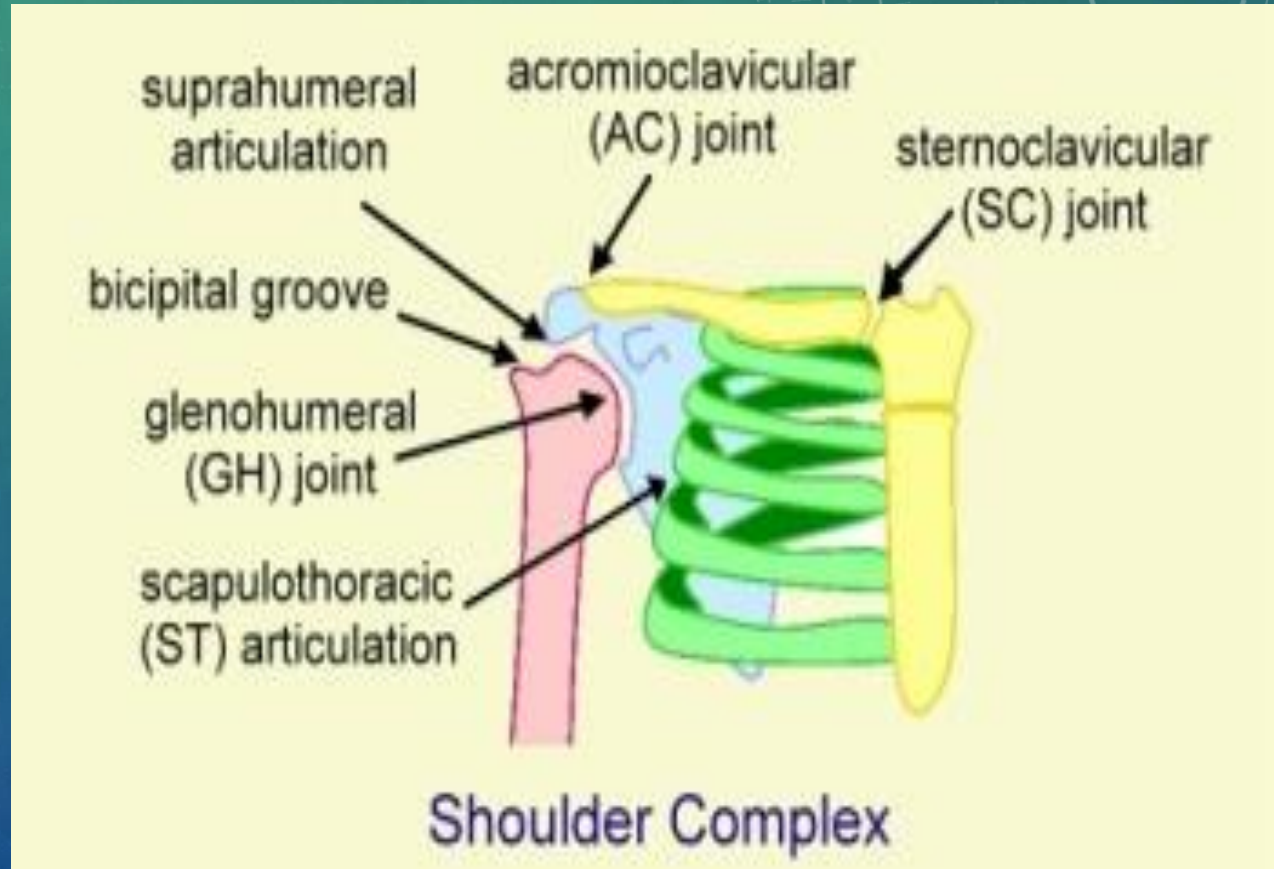
1) ARTICULAR ANATOMY / JOINTS

ANATOMICAL JOINTS:

- Gleno-humeral Joint
- Sterno-clavicular Joint
- Acromio-clavicular Joint

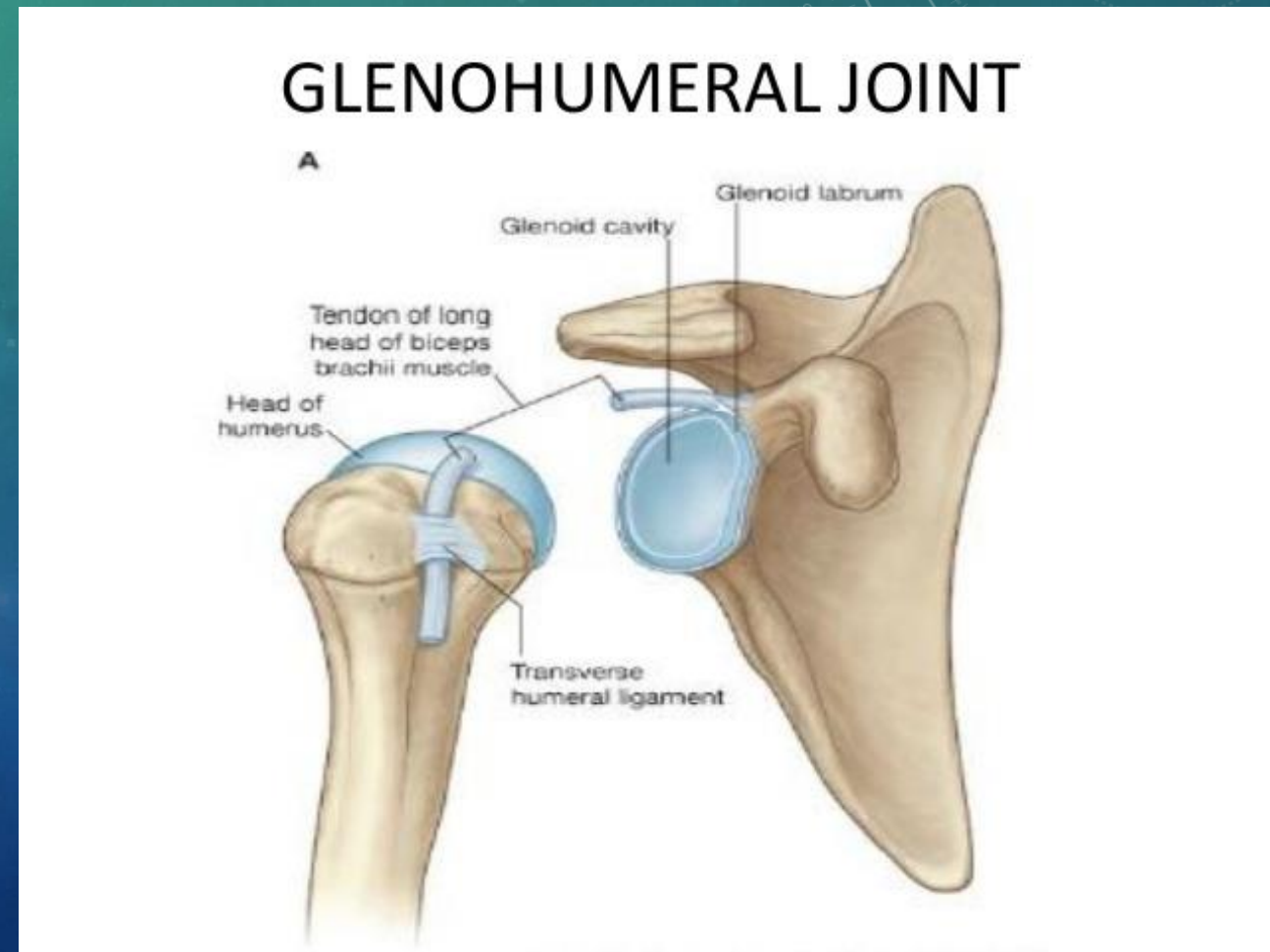
FUNCTIONAL JOINTS:

- Scapulo-thoracic Articulation
- Sub-Acromial Joint



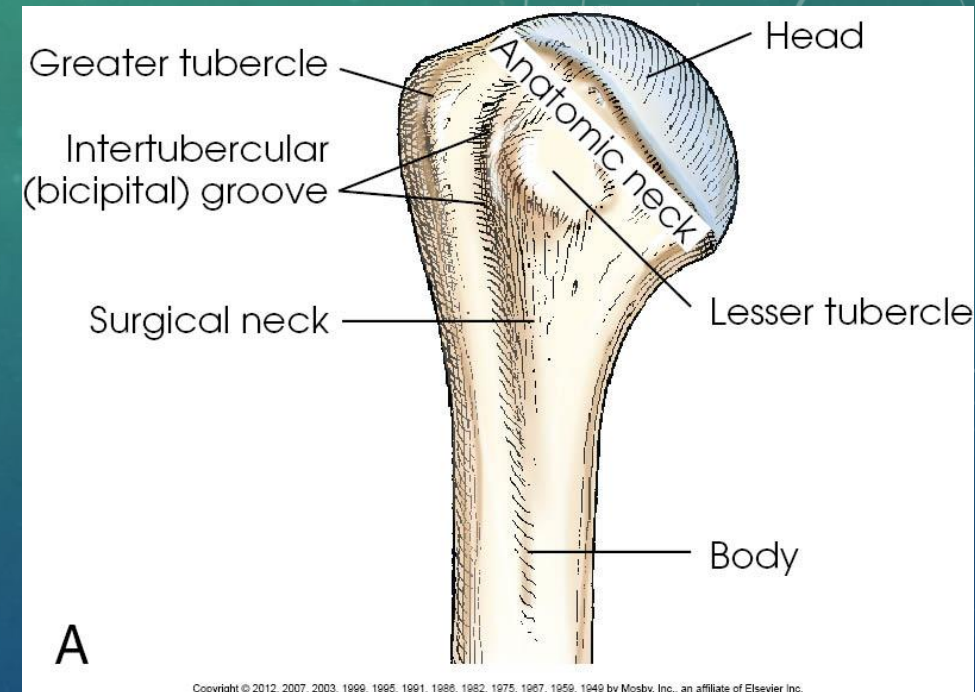
SHOULDER JOINT (GLENOHUMERAL JOINT)

- Its a synovial joint of ball and socket variety
- Articulating surfaces: head of humerus and glenoid cavity
- Structurally a weak joint (head of humerus is four times the size of glenoid cavity and the cavity is shallow), but the presence of glenoid labrum deepens the joint cavity



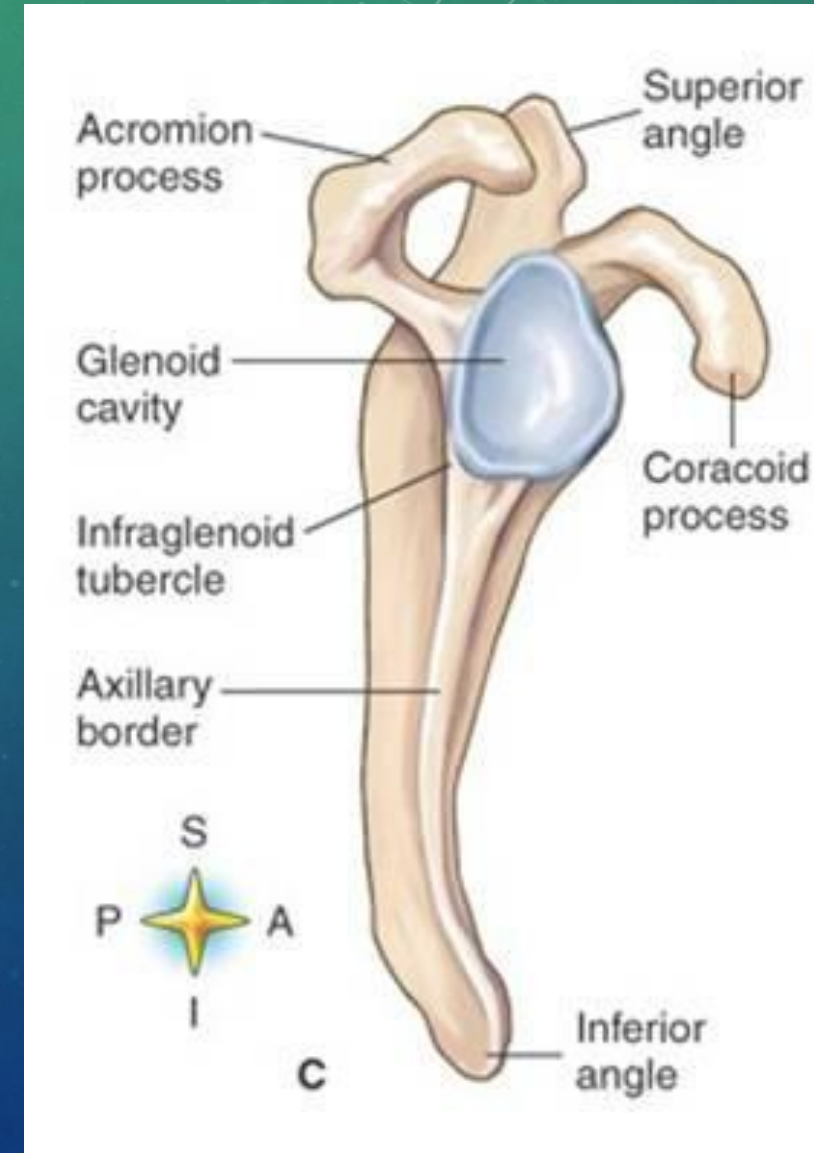
HEAD OF HUMERUS

- Hemispherical in form
- Directed upward, medially, and a little backward
- Humeral head and neck make an angle of 130-150 degrees with the shaft



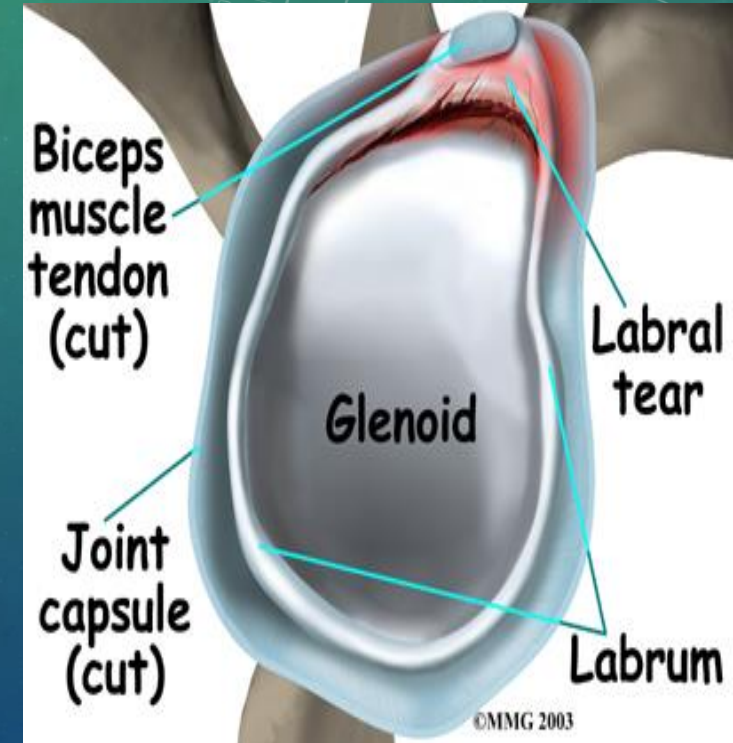
GLENOID CAVITY

- It is a shallow and pyriform in shape,
- located on the lateral angle of the scapula
- Directed laterally and forward
- Inclination angle 5 degree
- Articular cartilage
 - Thickest in periphery
 - Thinnest in centre



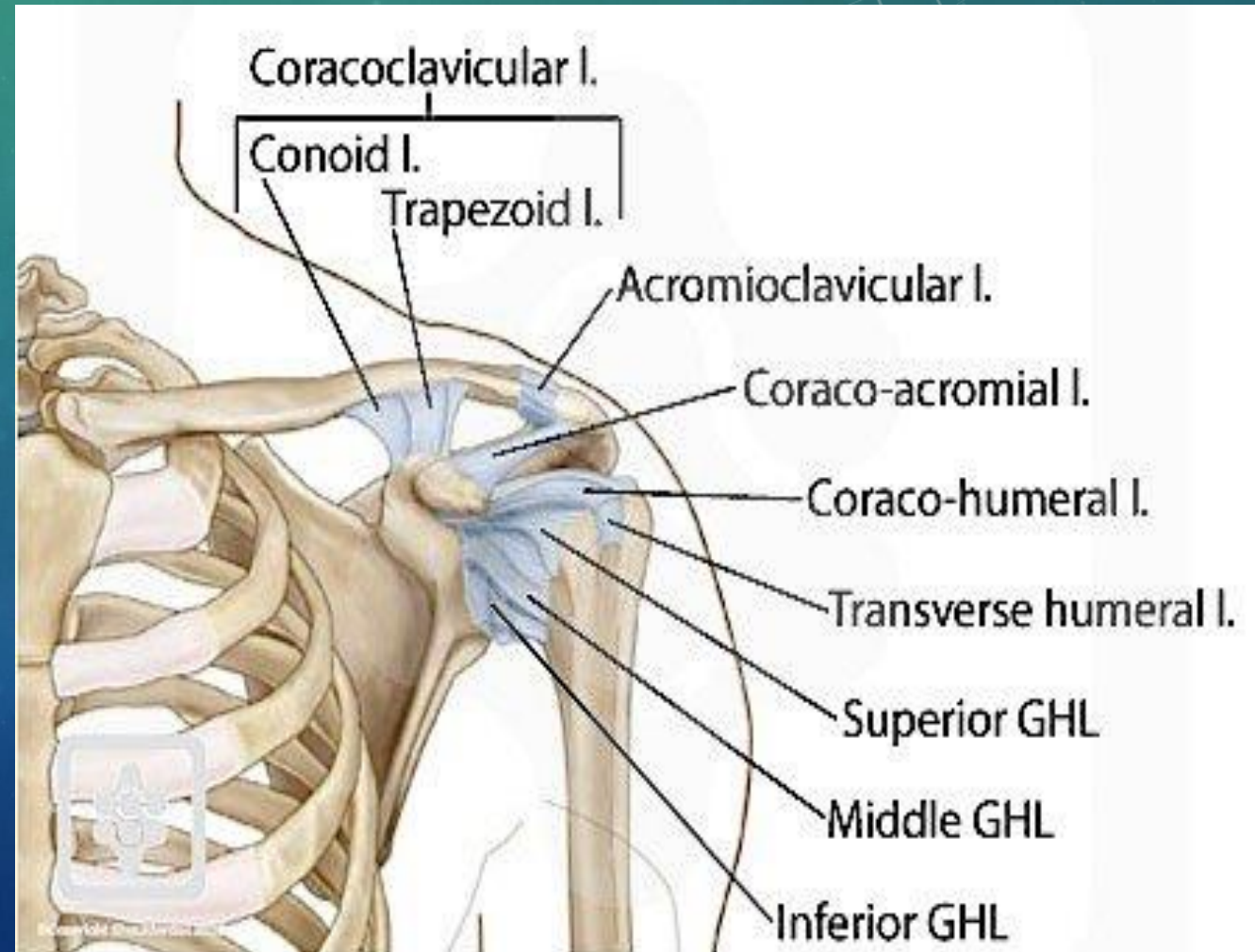
2) GLENOIDAL LABRUM

- It is a fibrocartilaginous rim attached around the margin of the glenoid cavity
- It deepens the glenoid cavity
- It is triangular in section, the base is fixed to the circumference of the cavity, while the free edge is thin and sharp
- It is continuous above with the tendon of the long head of the biceps brachii, which



3) LIGAMENTS

1. Capsular Ligament
2. Glenohumeral Ligament
3. Coracohumeral Ligament
4. Transverse Humeral Ligament
5. Coracoacromial ligament
6. Acromioclavicular Ligament
7. Coracoclavicular Ligament



II) DYNAMIC STABILIZERS

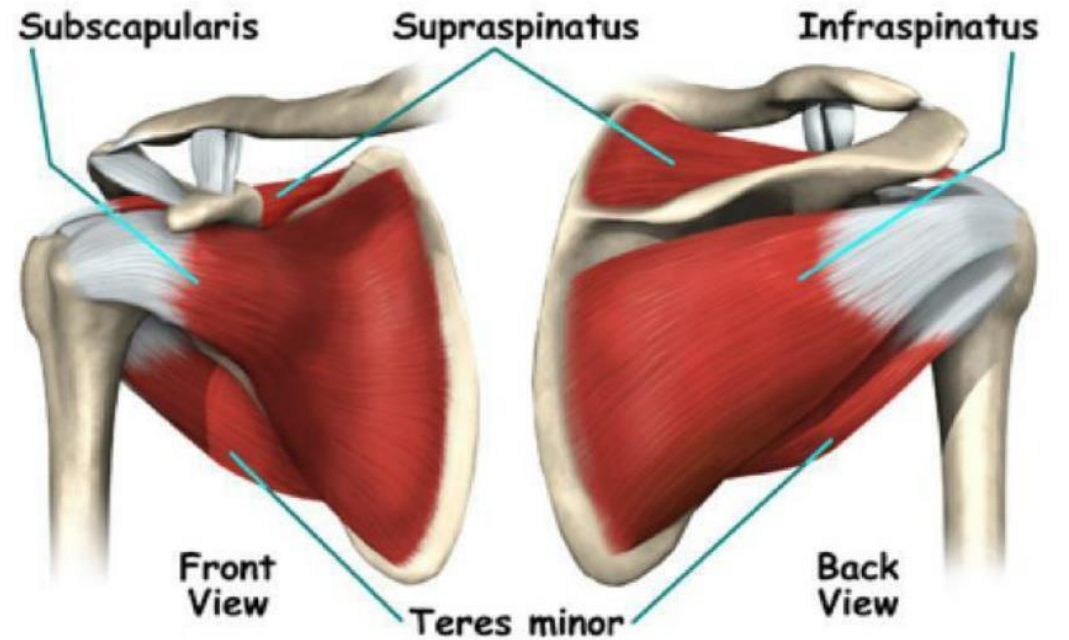
The background features a vertical gradient from green at the top to blue at the bottom. On the right side, there are several technical diagrams, including a large circular scale with numerical markings from 80 to 210 and arrows, and other smaller circular diagrams with arrows, suggesting a focus on engineering or control systems.

1) ROTATOR CUFF

- It is formed by
Supraspinatus,
Infraspinatus,
Teres minor &
Subscapularis

They connect the humerus to the scapula

Rotator Cuff



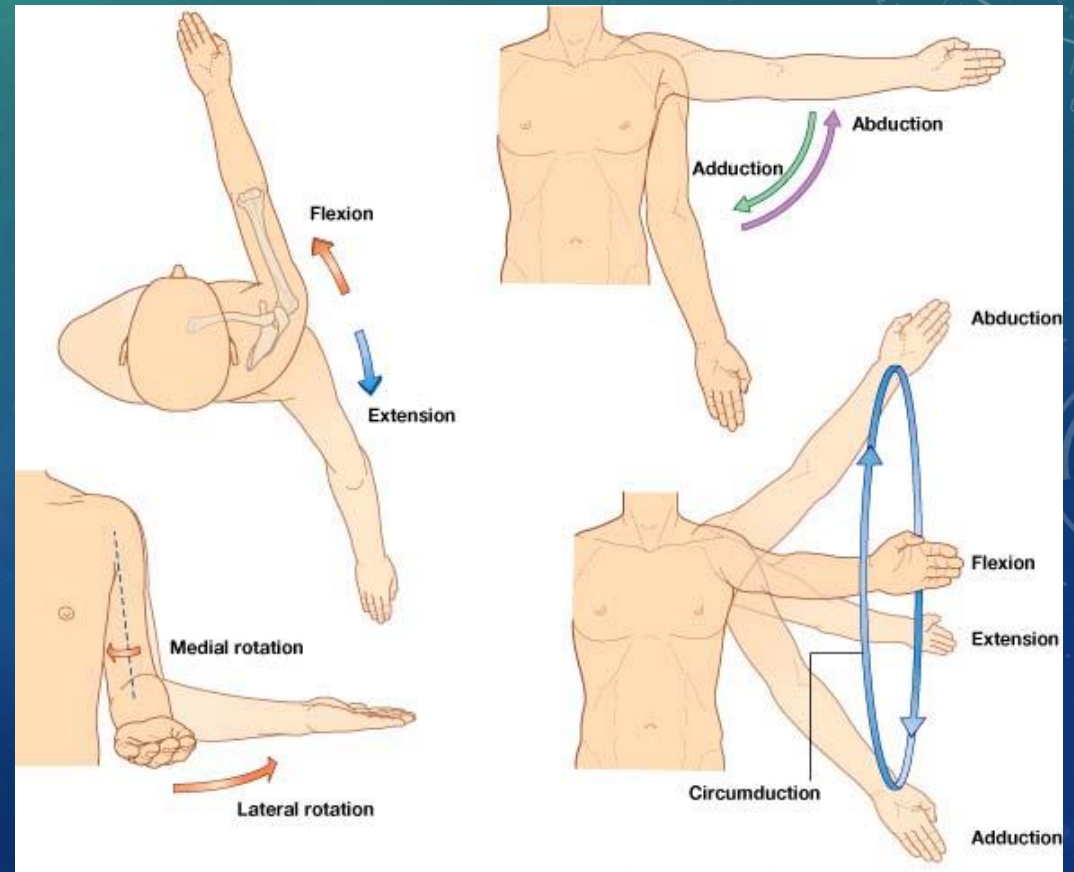
Muscle	Origin on scapula	Attachment on humerus	Function	Innervation
<i>Supraspinatus muscle</i>	supraspinous fossa	superior ^[2] facet of the greater tubercle	abducts the humerus	Suprascapular nerve (C5)
<i>Infraspinatus muscle</i>	infraspinous fossa	middle facet of the greater tubercle	externally rotates the humerus	Suprascapular nerve (C5-C6)
<i>Teres minor muscle</i>	middle half of lateral border	inferior facet of the greater tubercle	externally rotates the humerus	Axillary nerve (C5)
<i>Subscapularis muscle</i>	subscapular fossa	lesser tubercle	internally rotates the	Upper and Lower subscapular nerve

FUNCTIONS :

- They provide stability to the shoulder
- The muscles allow the shoulder to rotate
- Depresses the head of humerus into glenoid cavity when humerus moves
- Prevents compression of structures between humeral head and acromion

ACTIONS :

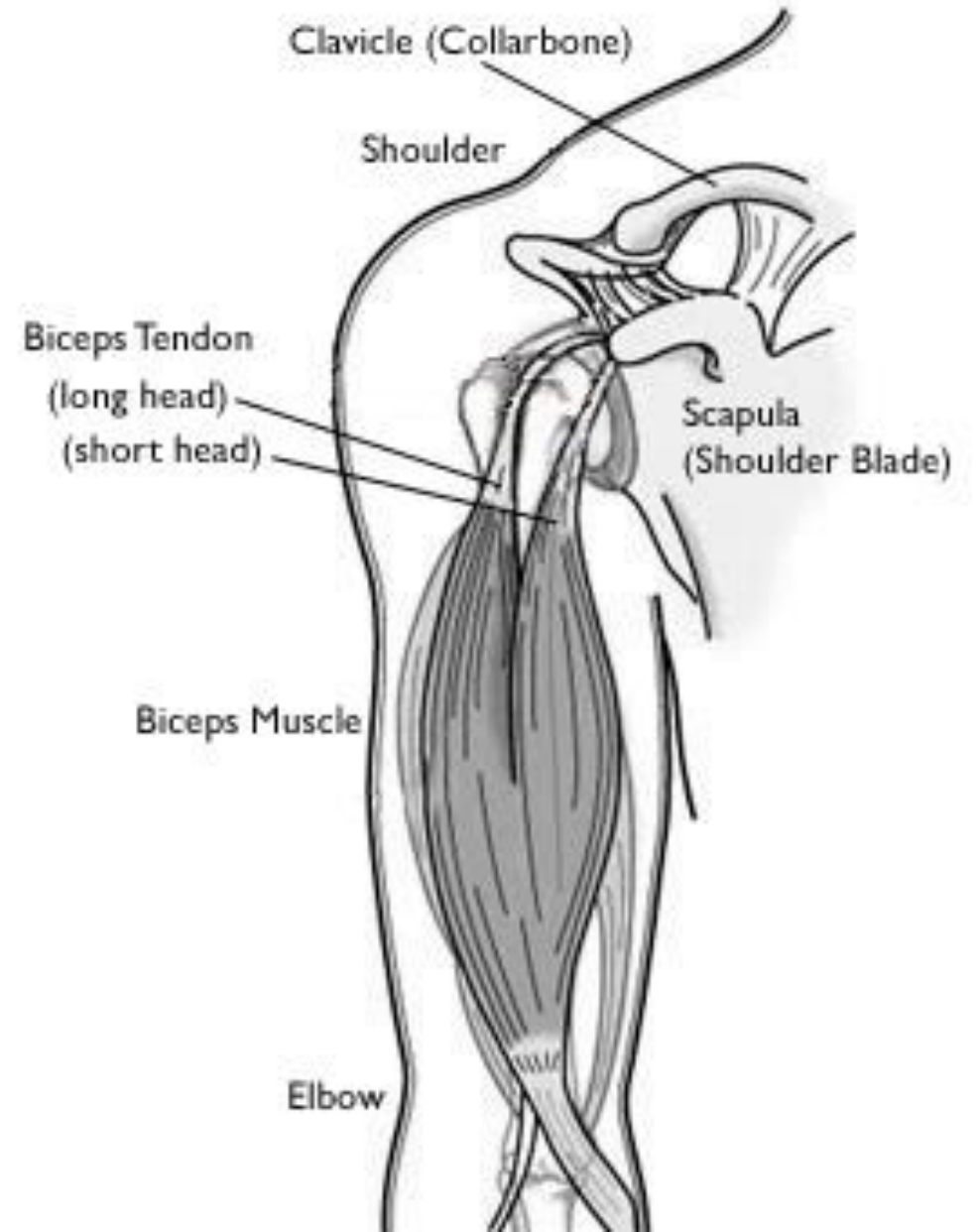
- **Supraspinatus** : Initiation of abduction
- **Subscapularis** : Internal rotation
- **Infraspinatus** : External rotation
- **Teres minor** : External rotation



2) BICEPS TENDON

The upper end of the biceps muscle has two heads

1. The long head attaches to the Supraglenoid tubercle
2. The short head attaches to the Coracoid process.



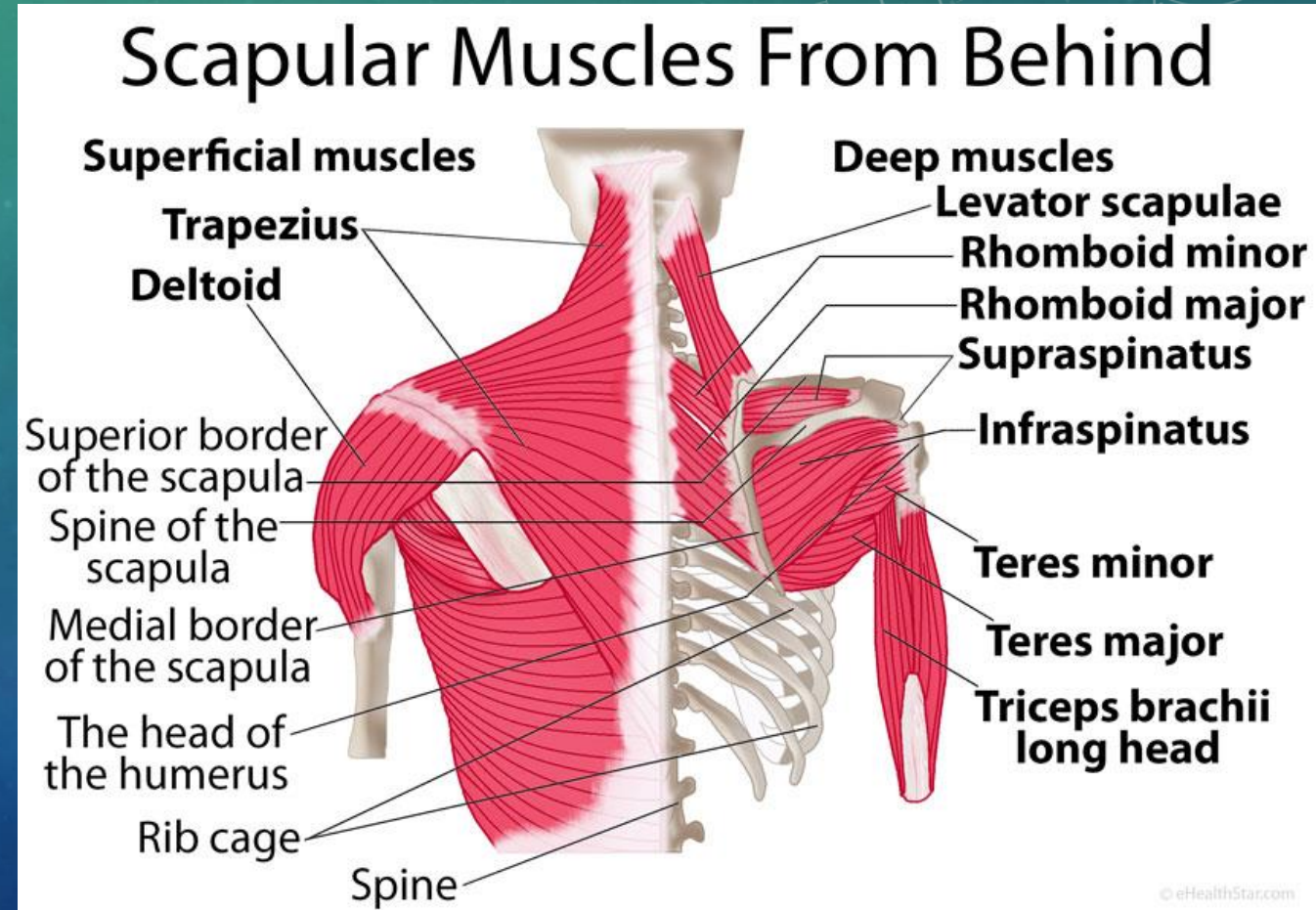
3) PERISCAPULAR MUSCLES

Superficial muscles

- Trapezius
- Deltoid

Deep Muscles

- Levator Scapulae
- Rhomboid Major
- Rhomboid Minor
- Supraspinatus
- Infraspinatus
- Teres Major
- Teres Minor
- Long Head of Triceps Brachii



SAHA'S CLASSIFICATION OF DYNAMIC STABILIZERS

- PRIME MOVERS : Deltoid and clavicular head of pectoralis major
- VERTICAL STEERERS : gravity and supraspinatus
- HORIZONTAL STEERERS : subscapularis and infraspinatus
- DEPRESSOR GROUP : pectoralis major, latissimus dorsi, teres major, teres minor

BURSAE AROUND SHOULDER

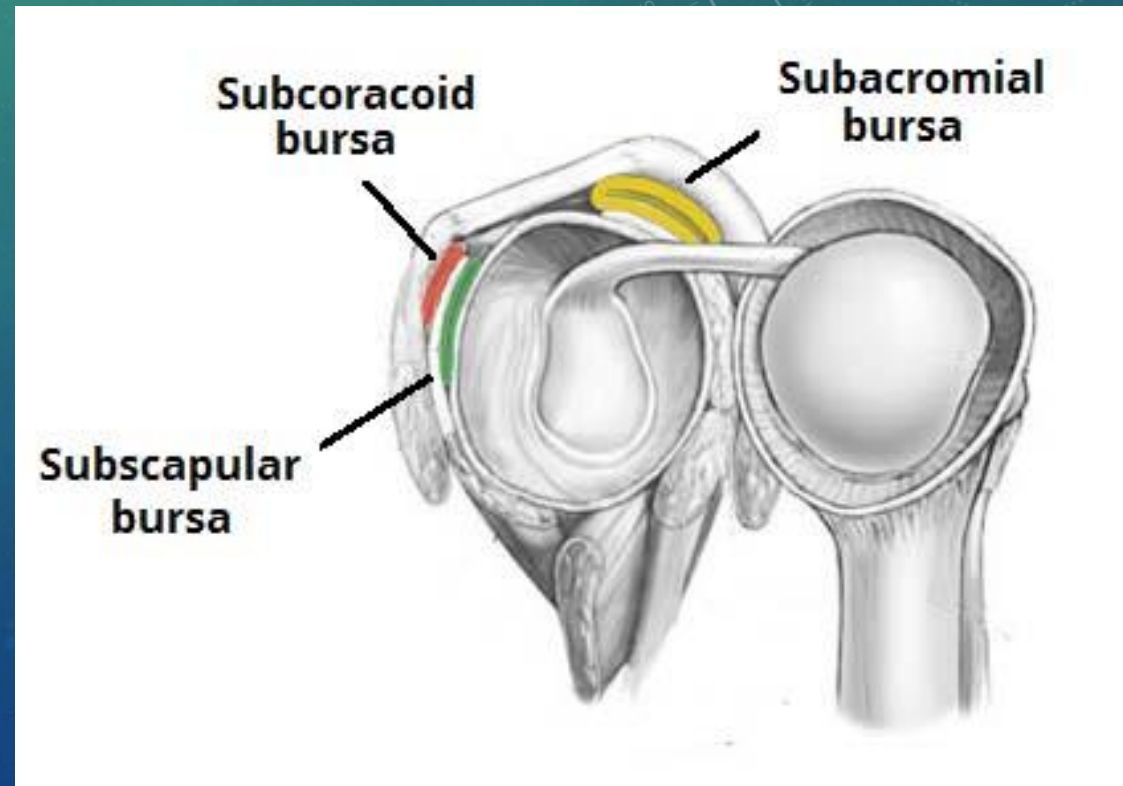
Subacromial Bursa

- located between the deltoid muscle and capsule extending under acromion and coracoacromial ligament
- Allows gliding between acromion and deltoid muscle
- Reduces friction on supraspinatus tendon

Subscapularis Bursa

- lies between subscapularis tendon and neck of scapula
- Protects the subscapularis tendon

Infraspinatus Bursa



NERVE SUPPLY

Axillary Nerve -

supplies the Deltoid muscle & Teres Minor

Long Thoracic Nerve -

supplies Serratus Anterior muscle

Suprascapular Nerve -

supplies **Supraspinatus** and **Infraspinatus** muscles

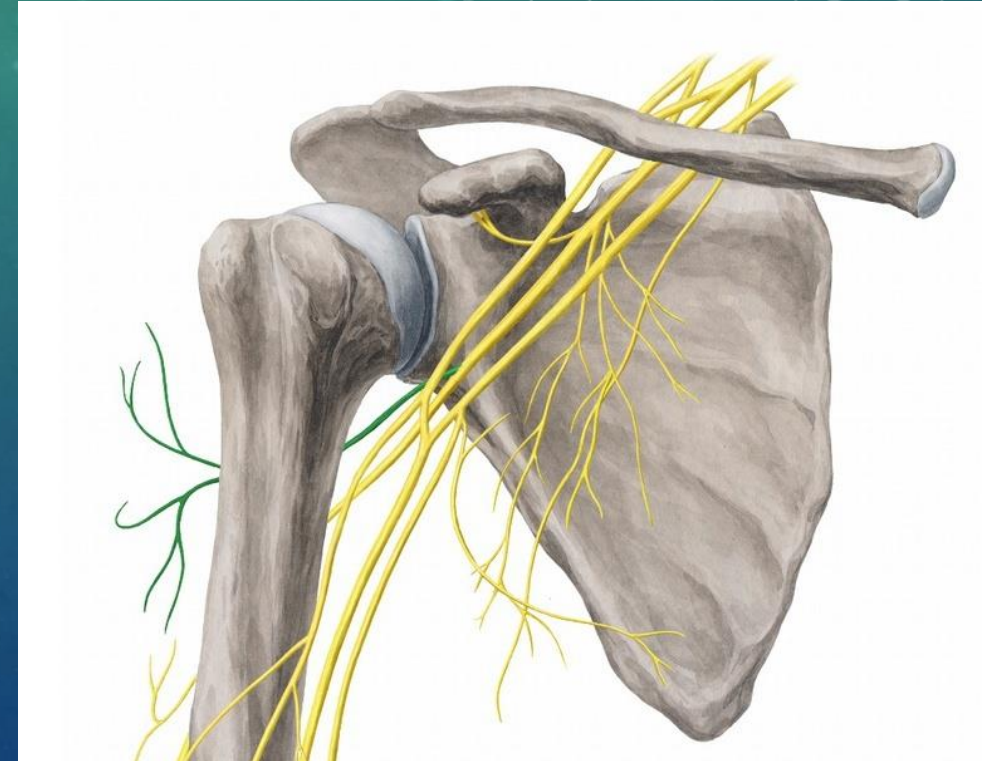
Musculocutaneous Nerve -

supplies the Biceps muscle

Subscapular Nerve -

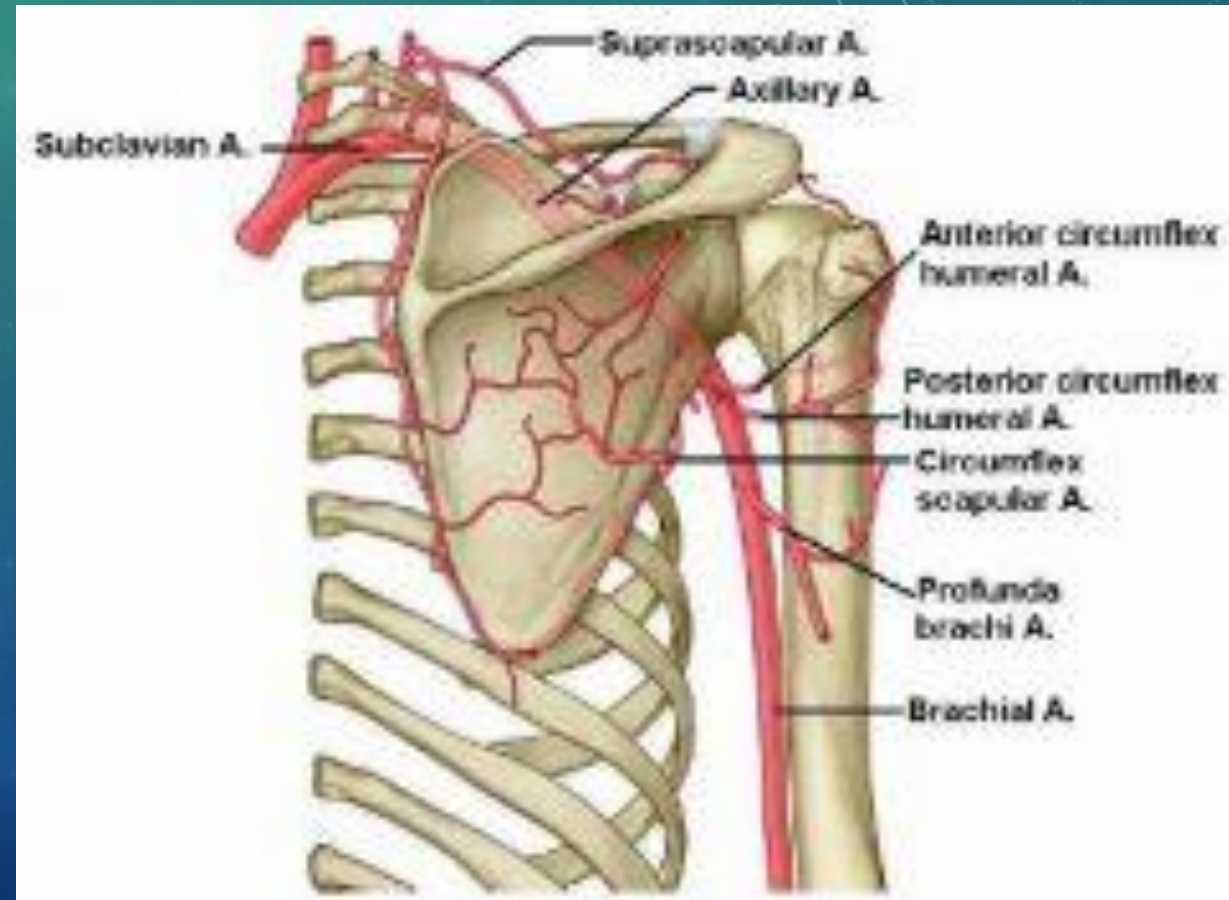
Supplies Subscapularis muscle

Sensory branches of Axillary nerve supplies the inferior surface of the deltoid called the **Regimental area**



BLOOD SUPPLY

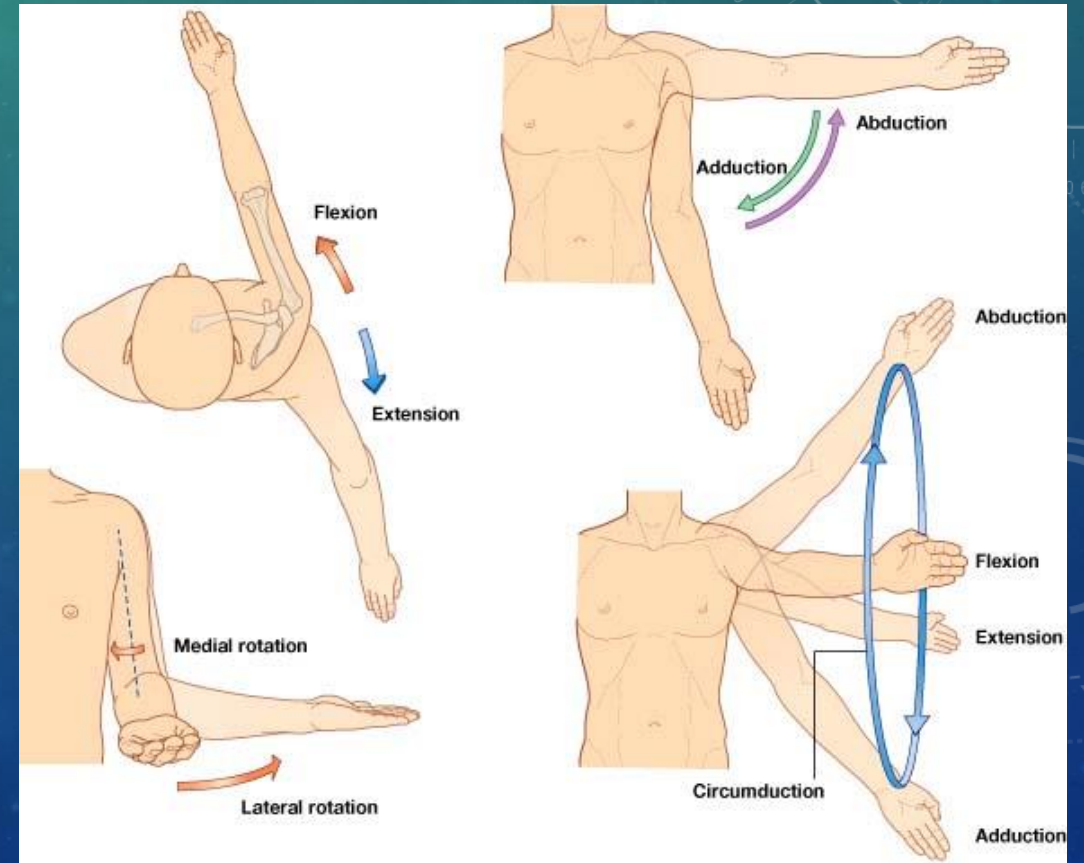
- Anterior Circumflex Humeral Vessels
- Posterior Circumflex Humeral Vessels
- Suprascapular Vessels
- Subscapular Vessels



MOVEMENTS AT SHOULDER JOINT

Movements at the Shoulder Joint

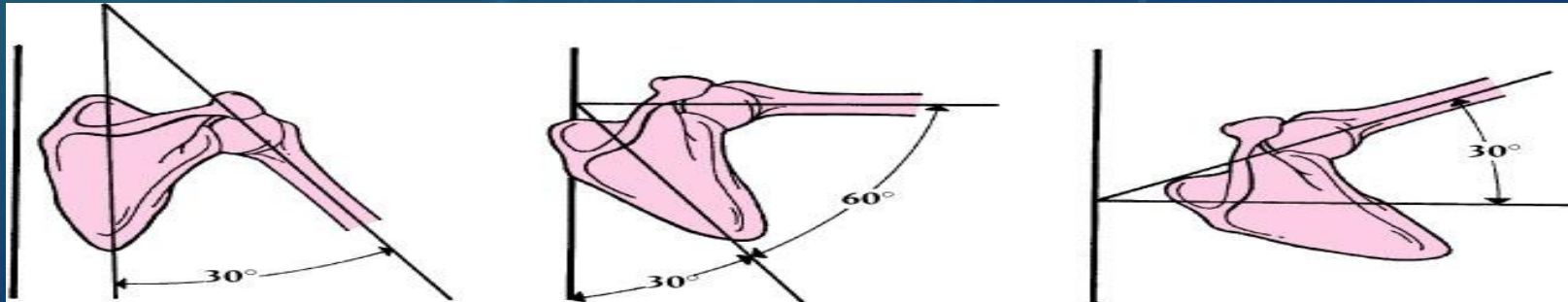
- Flexion
- Extension
- Abduction
- Adduction
- Medial Rotation
- Lateral Rotation




SCAPULO- HUMERAL RHYTHM

MOVEMENT OF SCAPULA RELATIVE TO THE HUMERUS

1. INITIAL 30 DEGREES OF GLENOHUMERAL ABDUCTION DOES NOT INCORPORATE SCAPULAR MOTION (SETTING PHASE)
2. 30 TO 90 DEGREES THE SCAPULA ABDUCTS AND UPWARDLY ROTATES 1 DEGREE FOR EVERY 2 DEGREES OF HUMERAL ELEVATION
3. ABOVE 90 DEGREES THE SCAPULA AND HUMERUS MOVE IN 1:1 RATIO

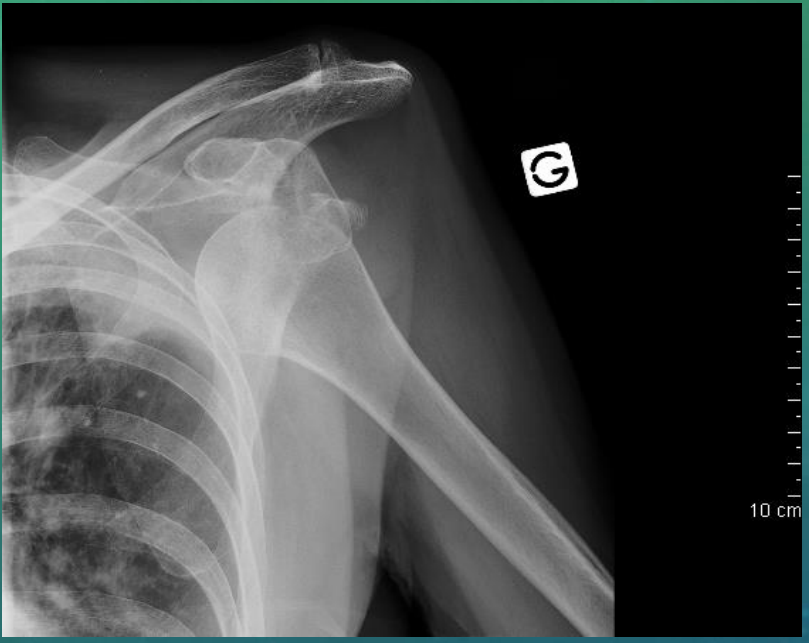


ANTERIOR DISLOCATION OF SHOULDER JOINT

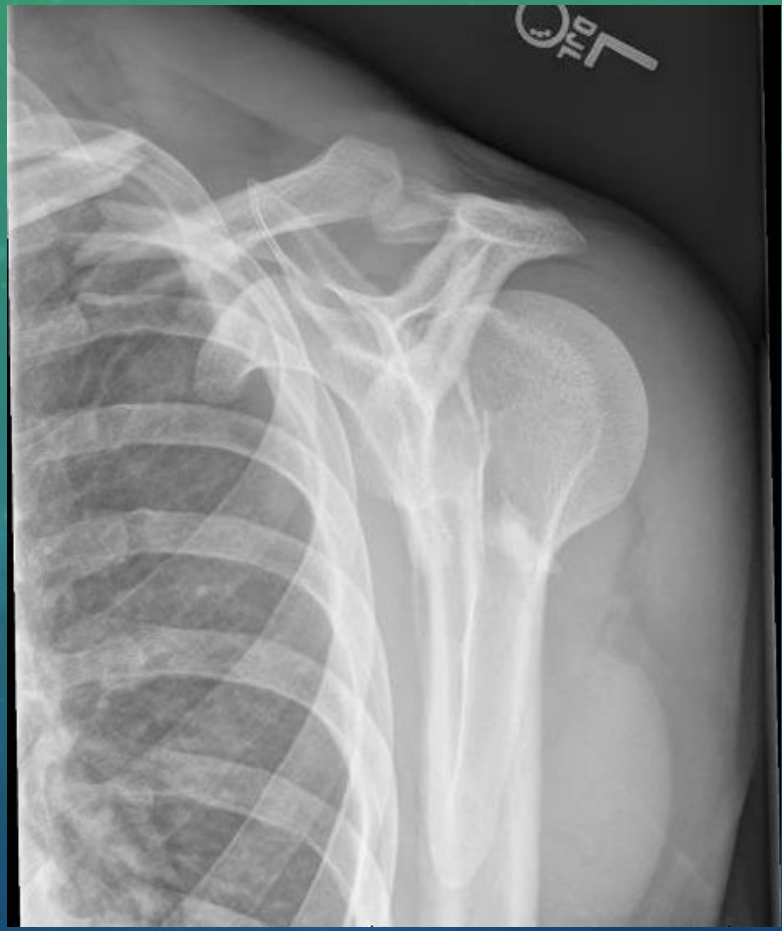

CLASSIFICATION OF SHOULDER INSTABILITY.

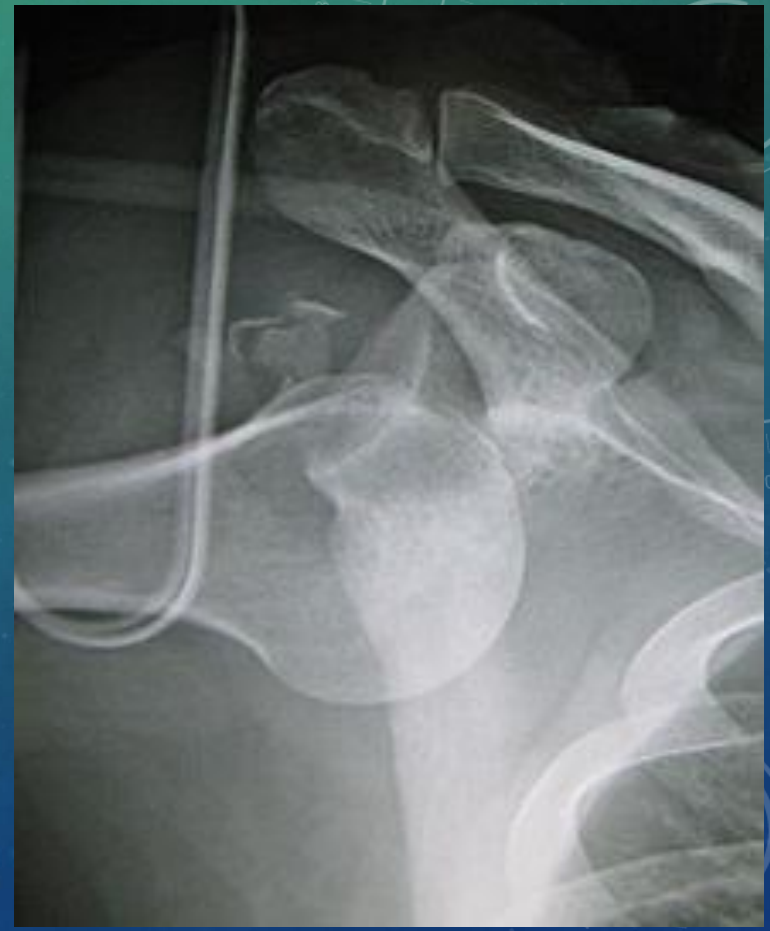- **ANATOMIC:**
Anterior, Posterior, Inferior
- **SEVERITY:**
Subluxation & Dislocation.
- **DURATION:**
Acute & Chronic.
- **OCCURRENCE:**
Single & Recurrent.
- **MECHANISM:**
Traumatic & Atraumatic.



Anterior Dislocation



Posterior Dislocation



Inferior Dislocation

1) MECHANISM OF INJURY

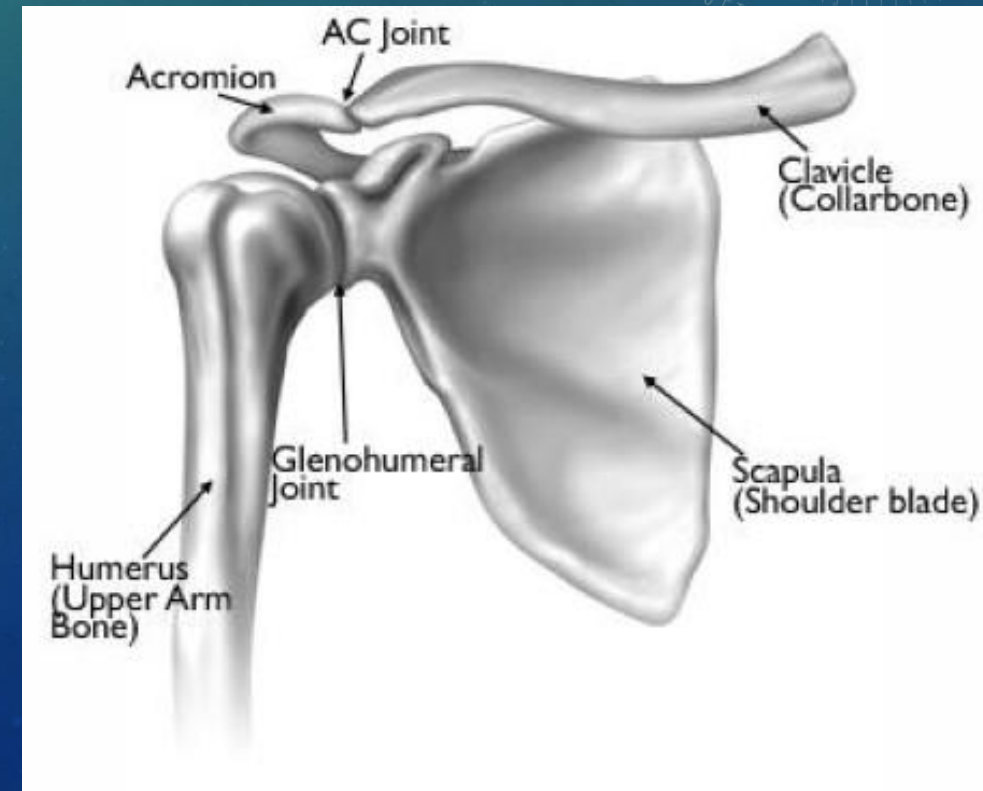
- 98% of dislocations were Anterior 2% were Posterior/ Inferior dislocations

MECHANISM OF INJURY:

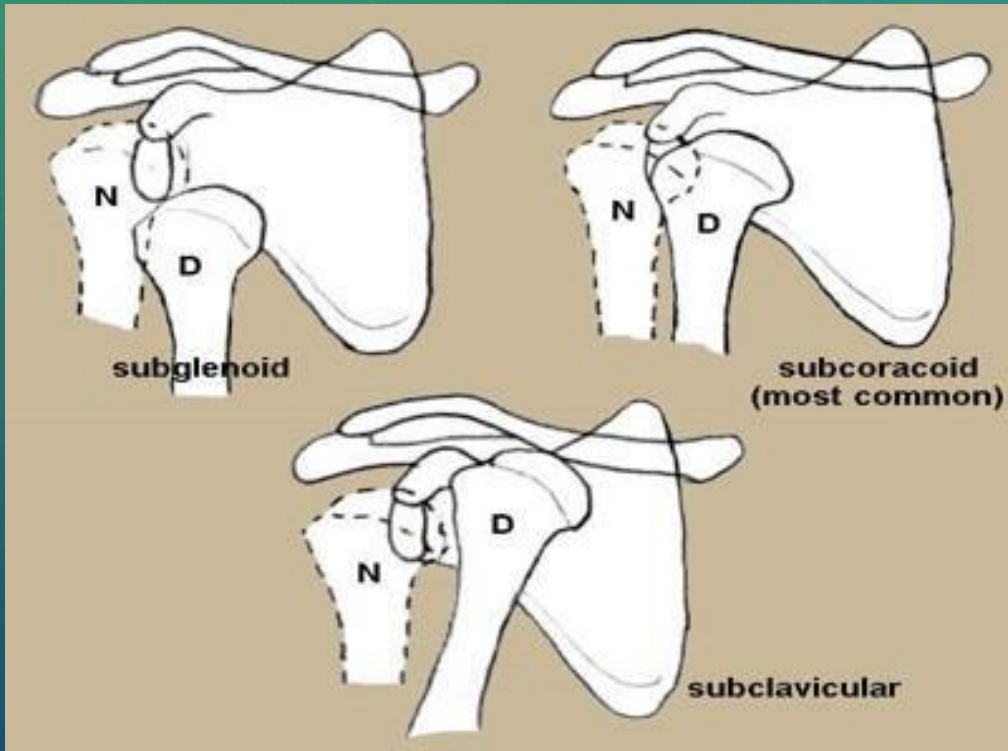
- Indirect trauma to the shoulder in apposition of abduction, extension & external rotation –
MORE COMMON
- Direct trauma- An anteriorly directed impact to the posterior shoulder typically.

2) REASONS FOR DISLOCATION

- Size of humeral head is 4 times larger than glenoid cavity
- Inferior aspect of shoulder joint is not covered with muscles
- Gravity aids for dislocation
- Lack of bony stability
- No neck shaft angle.



3) TYPES OF ANTERIOR DISLOCATION:

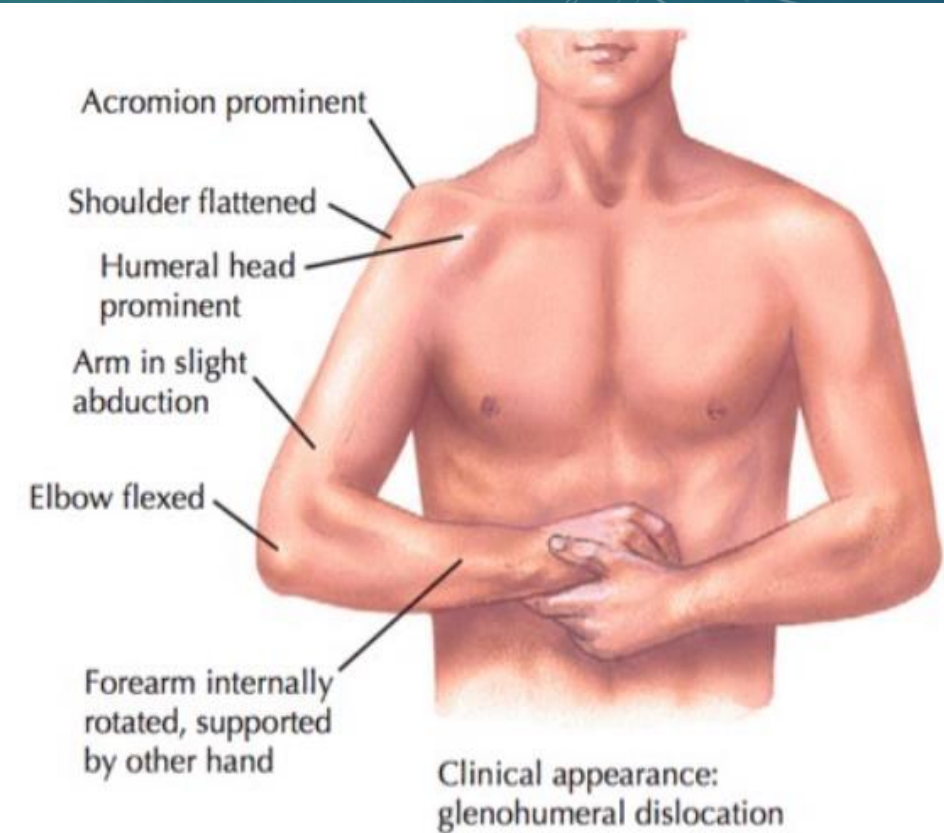


- **SUBCORACOID** (most common)
- **SUB-GLENOID**
- **SUBCLAVICULAR**

4) CLINICAL FEATURES

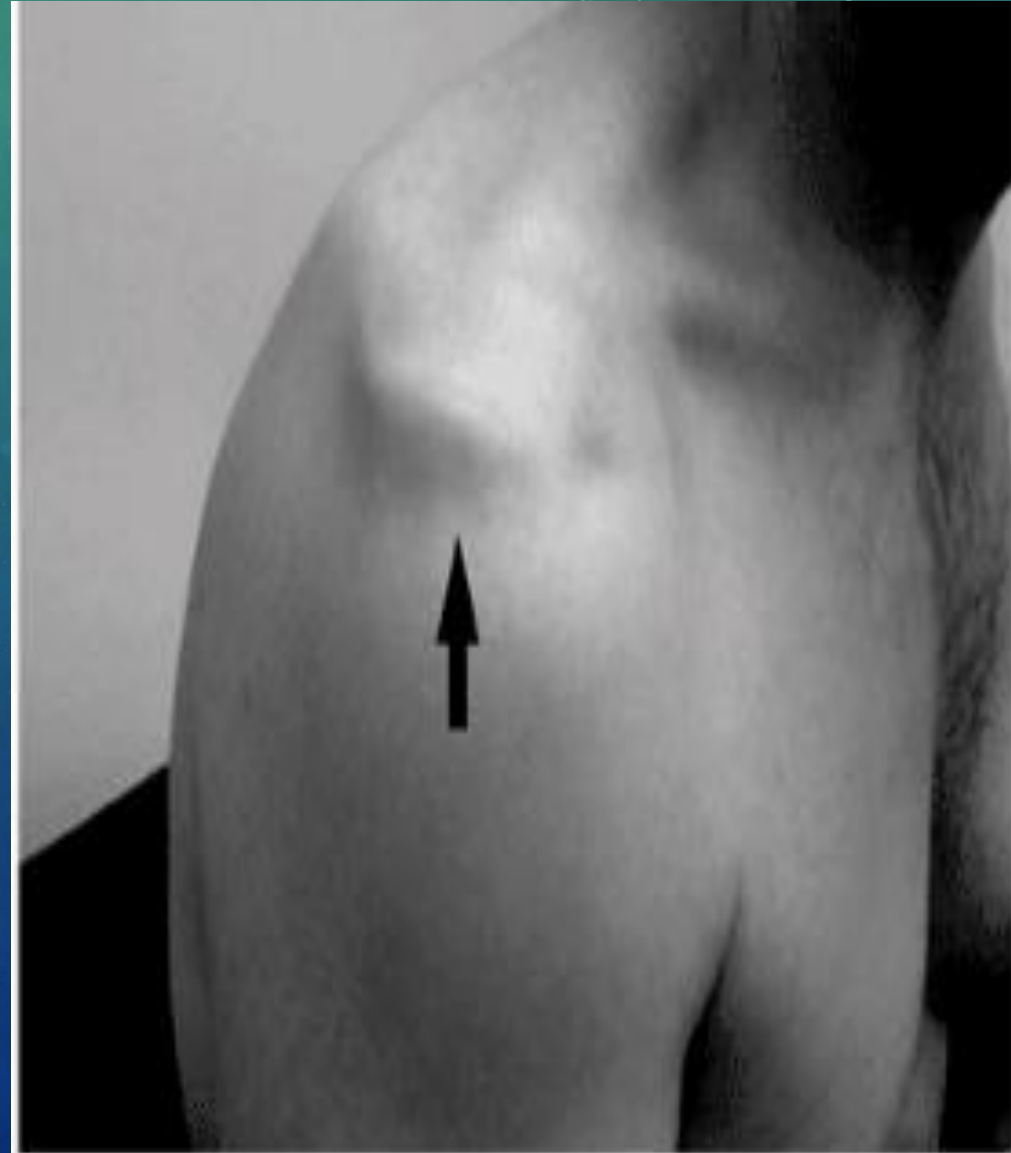INSPECTION

- ATTITUDE – Shoulder in abduction and external rotation, with affected limb's forearm being supported by the normal limb
- Loss of Deltoid Contour
- Prominence of Acromion process
- Mass in the anterior aspect of shoulder



PALPATION

- Severe Pain / Tenderness in the joint
- Restriction of Range of movements
- Hollowness beneath the acromion process
(due to absence of humeral head)
- Positive clinical tests



CLINICAL TESTS

- **Dugas test** : patient is unable to touch the opposite shoulder with the hand of affected side.
- **Hamilton's ruler test** : Normally a ruler placed over the lateral aspect of the arm will not touch acromion & lateral epicondyle simultaneously due to deltoid muscle bulk. In dislocation, the ruler will touch both acromion & lateral epicondyle simultaneously as the deltoid contour is lost.

- **Bryant's test:** Anterior axillary fold will appear elongated compared to opposite side.
- **Callaways test :** The circumference/girth of the axilla is increased when compared to opposite side.
- **Apprehension test:** It's a provactive test.

When the shoulder is abducted & externally rotated until its maximum limit, the patient will report immense pain.

- **Examination of axillary nerve:** Loss of sensation in the inferior surface of deltoid (Regimental area) due to injury to the **axillary nerve**.

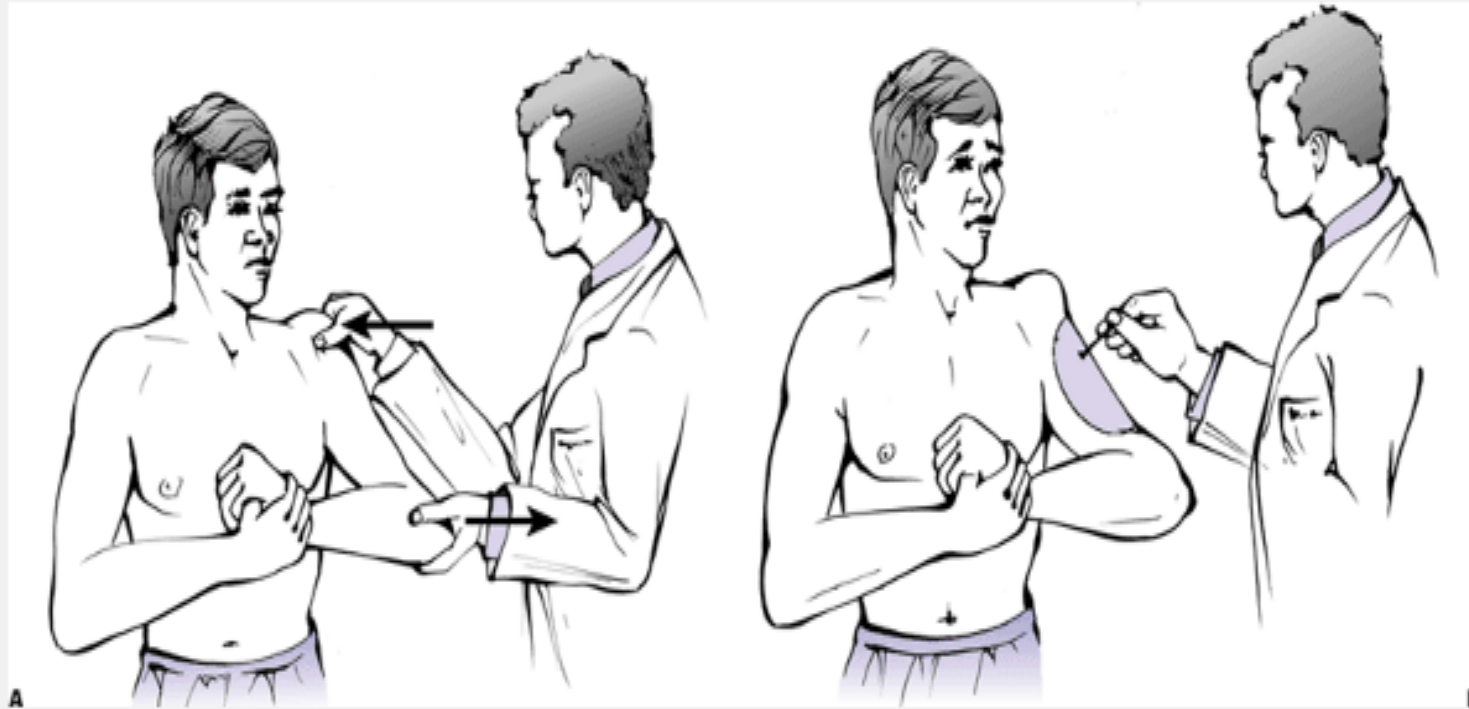
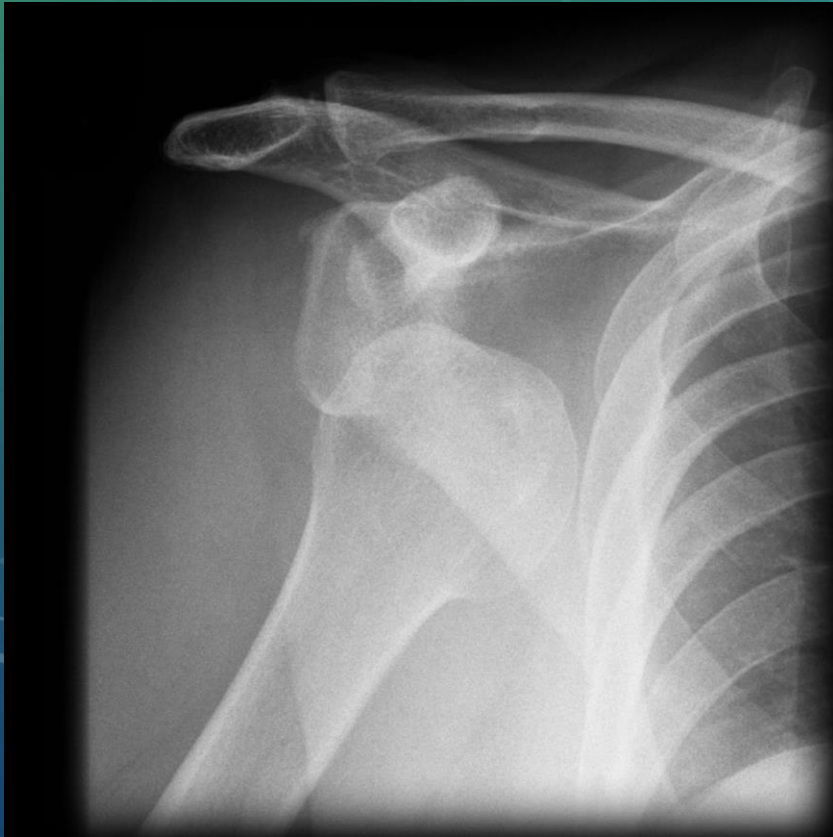

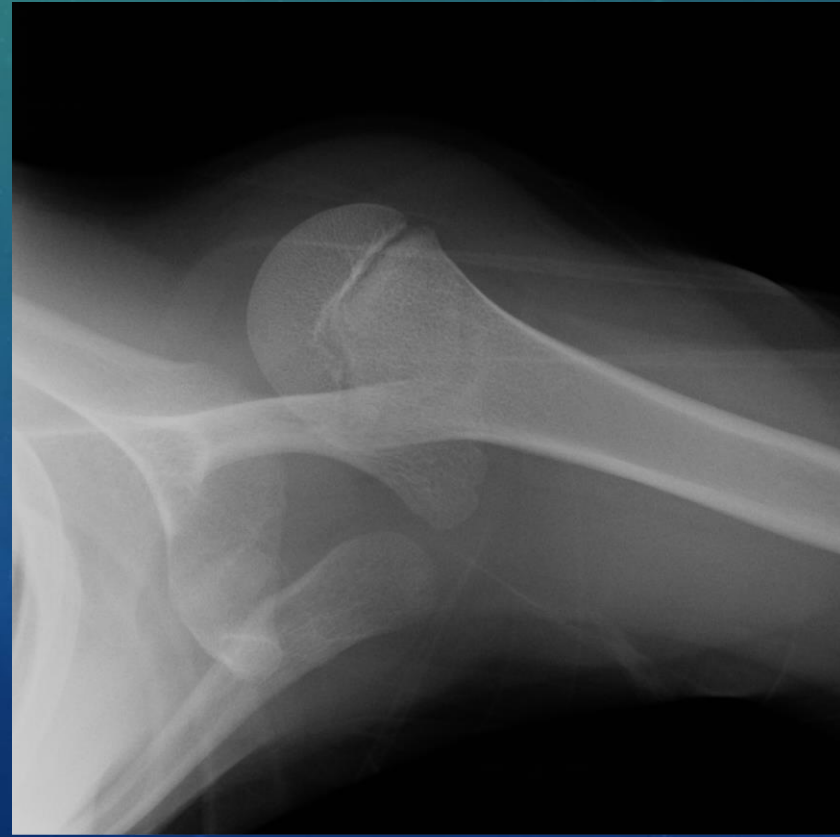FIGURE 34-4 Technique for testing axillary nerve function. With the arm adducted and stabilized by the examiner, the patient is asked to abduct the arm. Motor component **(A)** of the axillary nerve is documented by observing or palpating deltoid muscle contraction. Sensory component **(B)** of the axillary nerve is documented by testing the sensation to the lateral aspect of the upper arm.

5) INVESTIGATIONS

1) ANTERO-POSTERIOR VIEW

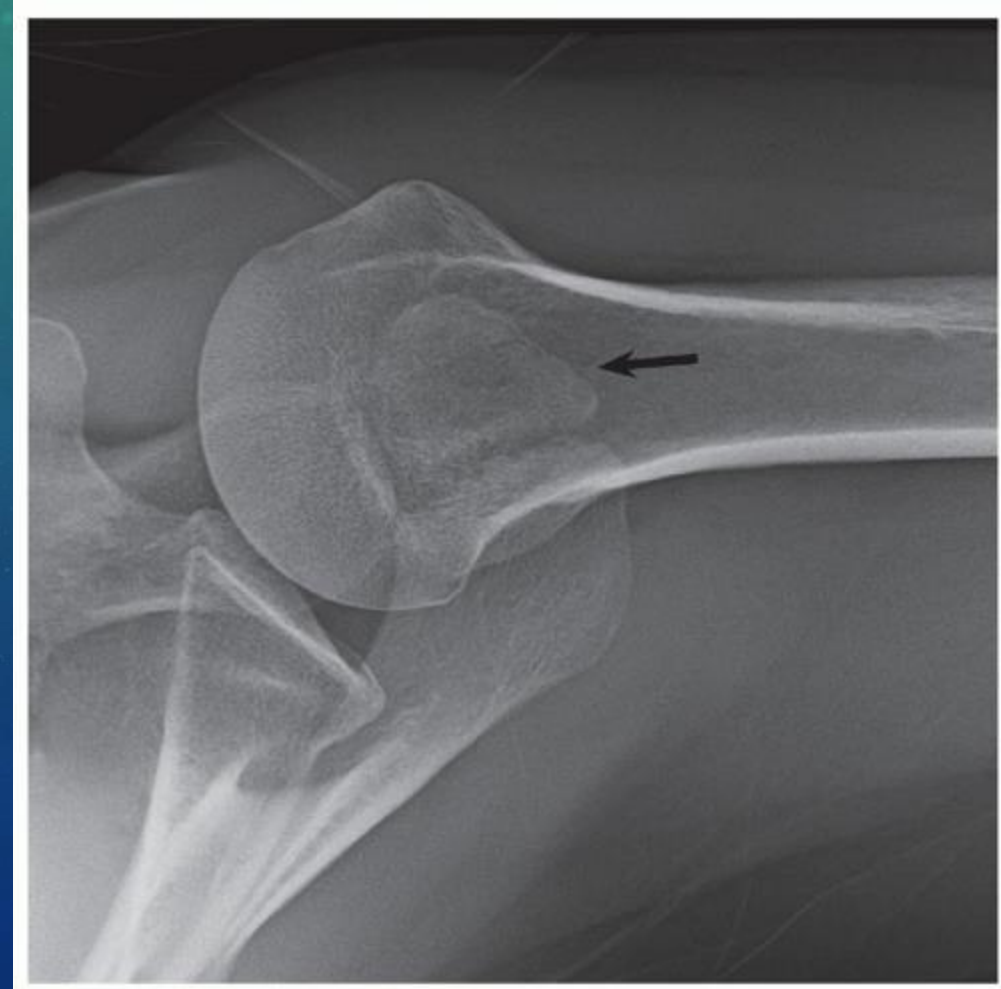
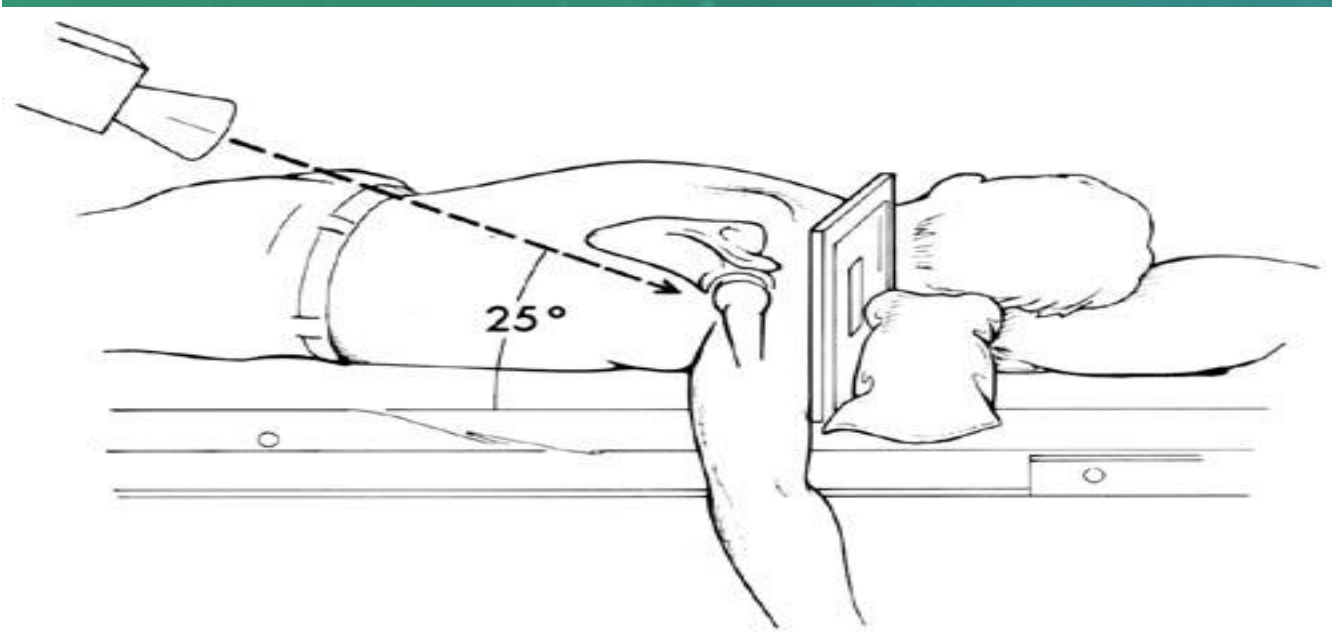


2) AXILLARY VIEW



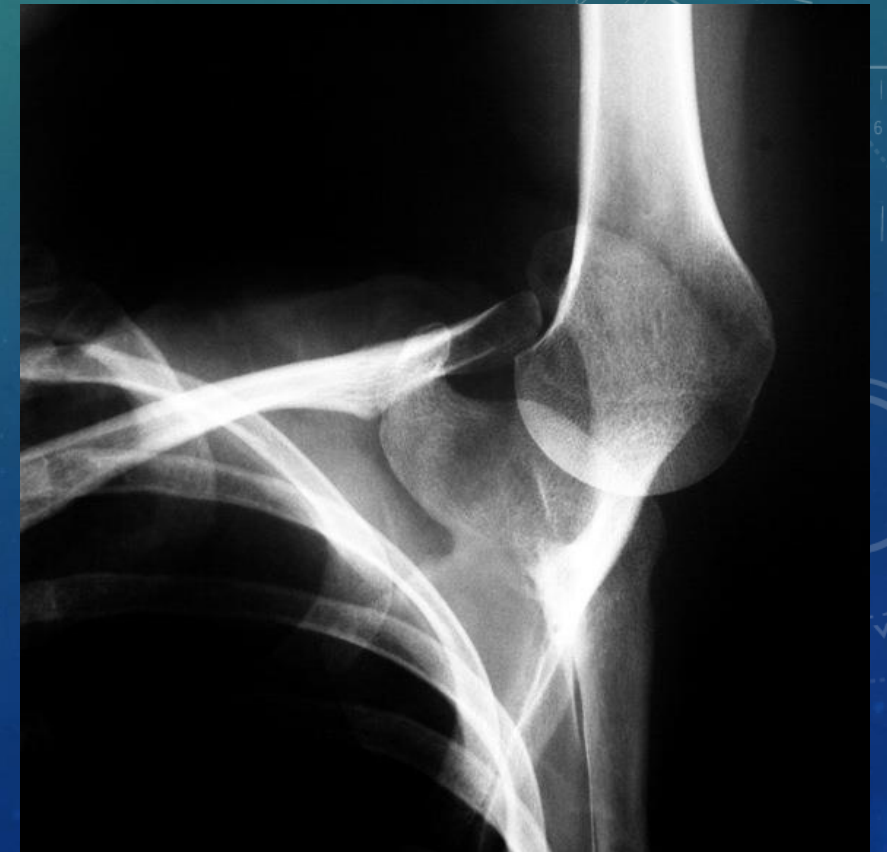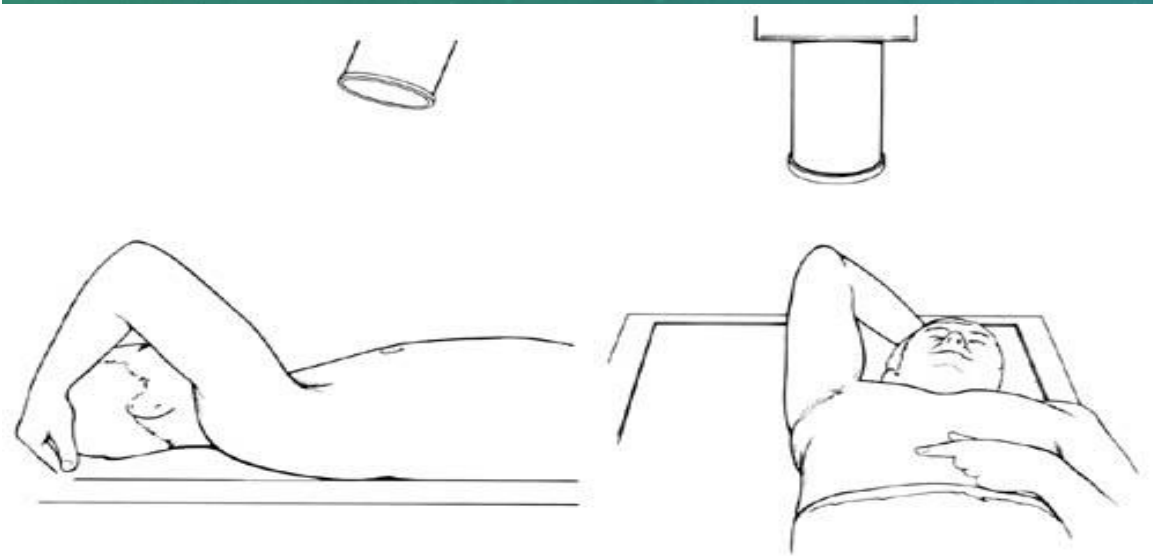
3) WEST POINT AXILLARY VIEW-

- With the patient in prone position, the xray beam is directed cephalad to the axilla 25 degree from horizontal and 25 degrees medial. It provides the tangential view of the antero-inferior Glenoid Rim. Helpful in identifying **Bankart's lesion**.



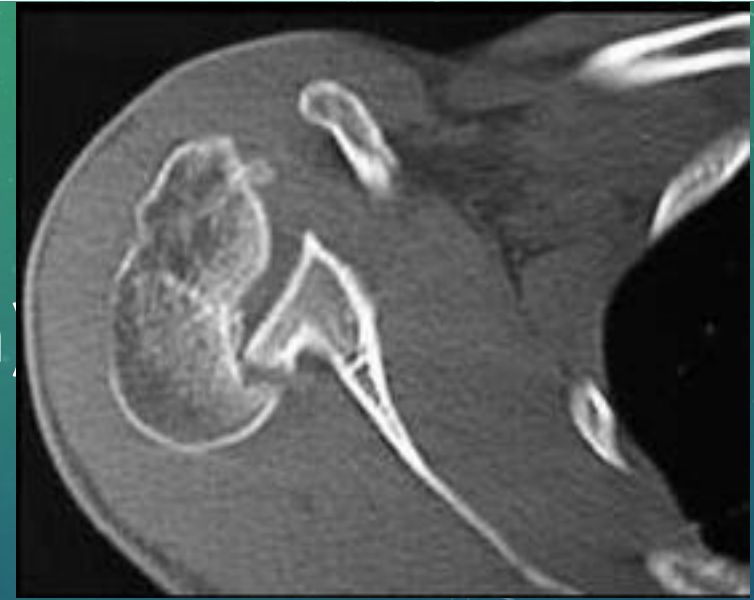
4) STRYKER NOTCH VIEW -

- Patient in supine position, the ipsilateral palm is placed over the crown of the head and the elbow pointing towards the ceiling. The xray beam is directed 10 degree cephalad to the coracoid process. This visualizes the **Hill-Sachs** lesion better.



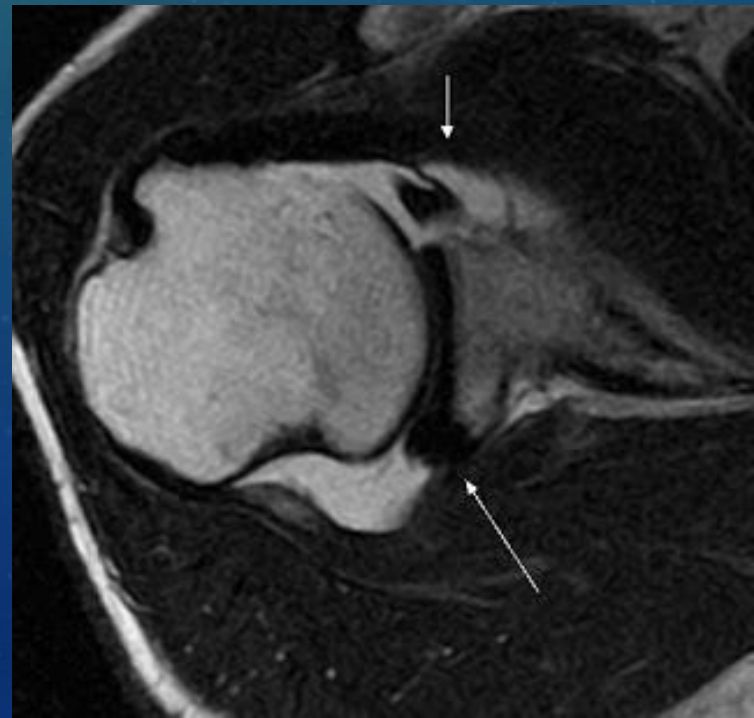
5) CT SCAN –

Visualizing humeral head fractures (Hill-sachs lesion)



6) MRI SCAN –

Visualizes Glenoid labrum / rim (Soft tissue Bankart / Bony Bankart lesions)



7) SINGLE CONTRAST ARTHROGRAPHY –

Rotator cuff pathologies

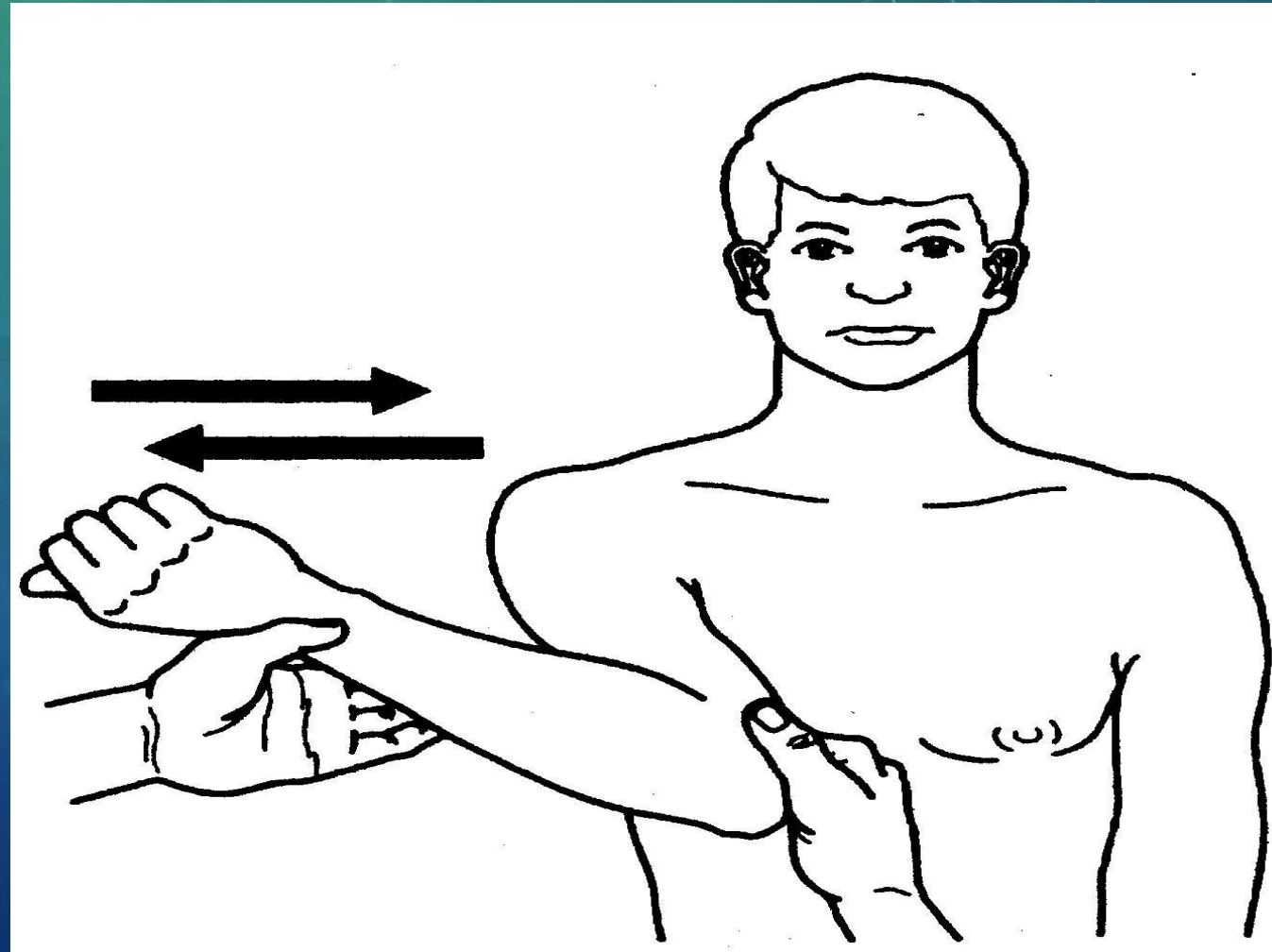
6) TREATMENT

1. CLOSED REDCUTION

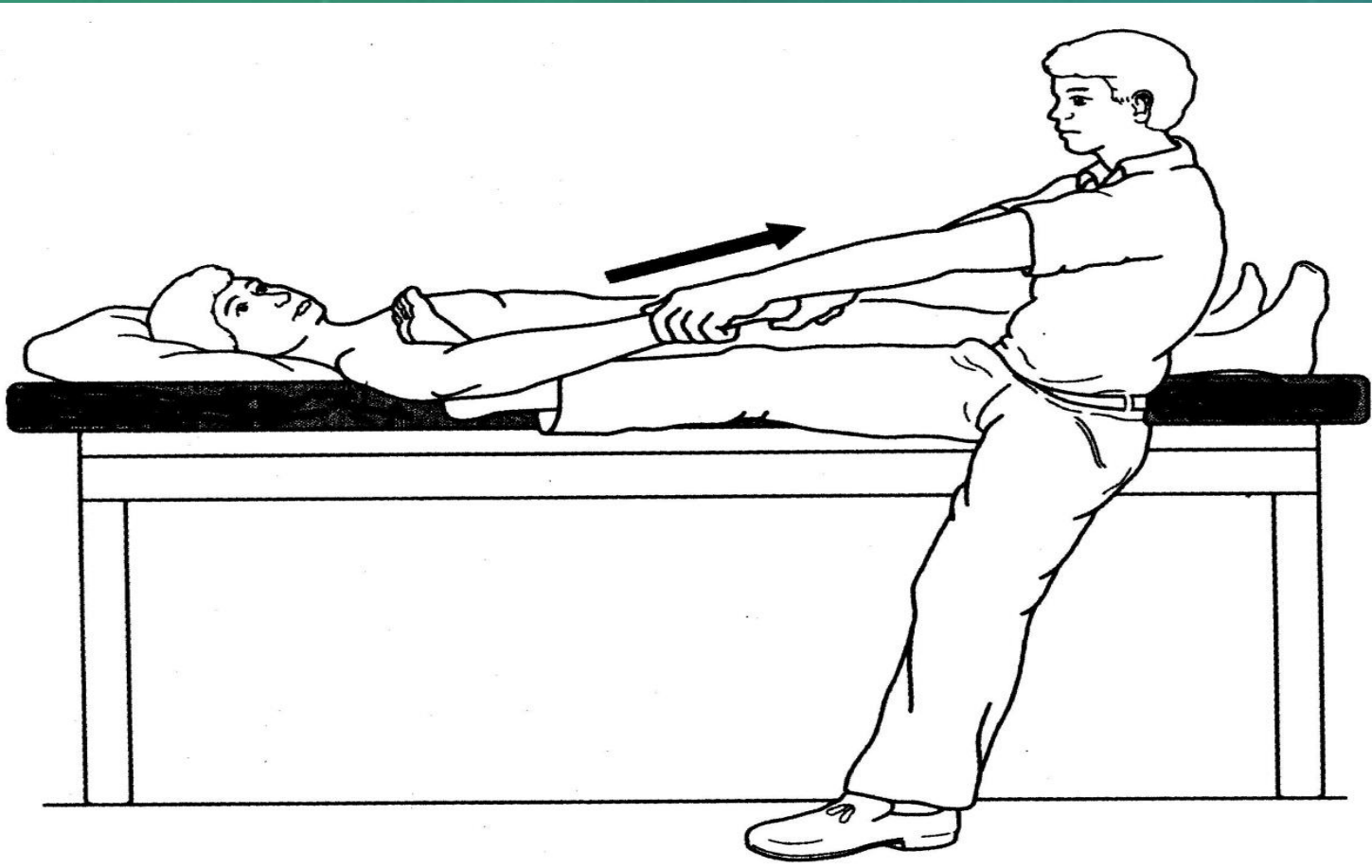
- Kocher maneuver
- Hippocratic Technique
- Stimson technique

Kocher maneuver

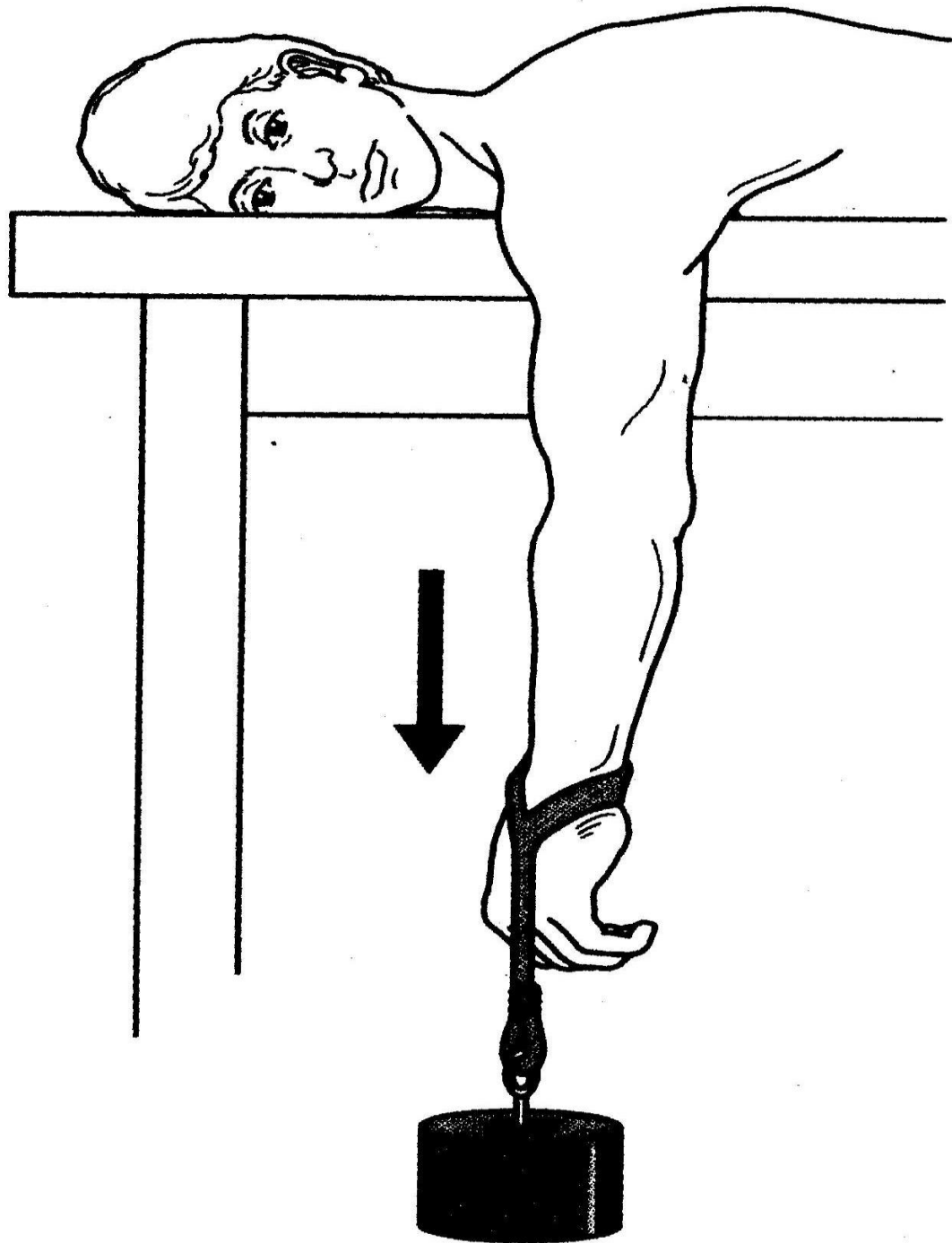
- Pt in supine position
- Hold the elbow
- Traction along long axis of humerus
- Externally rotate shoulder
- Adduction of arms
- Internally rotate the shoulder
- Counter traction is given simultaneously with a towel slung over the axilla



Hippocratic Technique



- The heel of the foot is placed against the axillary fold and longitudinal traction is given
- It was predominant earlier.
- Less traumatic



Stimson technique

- Patient sedated
- The patient is positioned prone
- The arm is allowed to hang down.
- 10 lb of weight is suspended over the wrist
- Reduction attained gradually

2) OPEN REDUCTION

Indications:

1. Soft tissue interposition.
2. Displaced greater tuberosity #.
3. Glenoid rim # > 5 mm in size.
4. Irreducible dislocations.

Procedure:

- Delto-pectoral approach.
- The dislocation is reduced by identifying & removing the causative factor for irreducibility

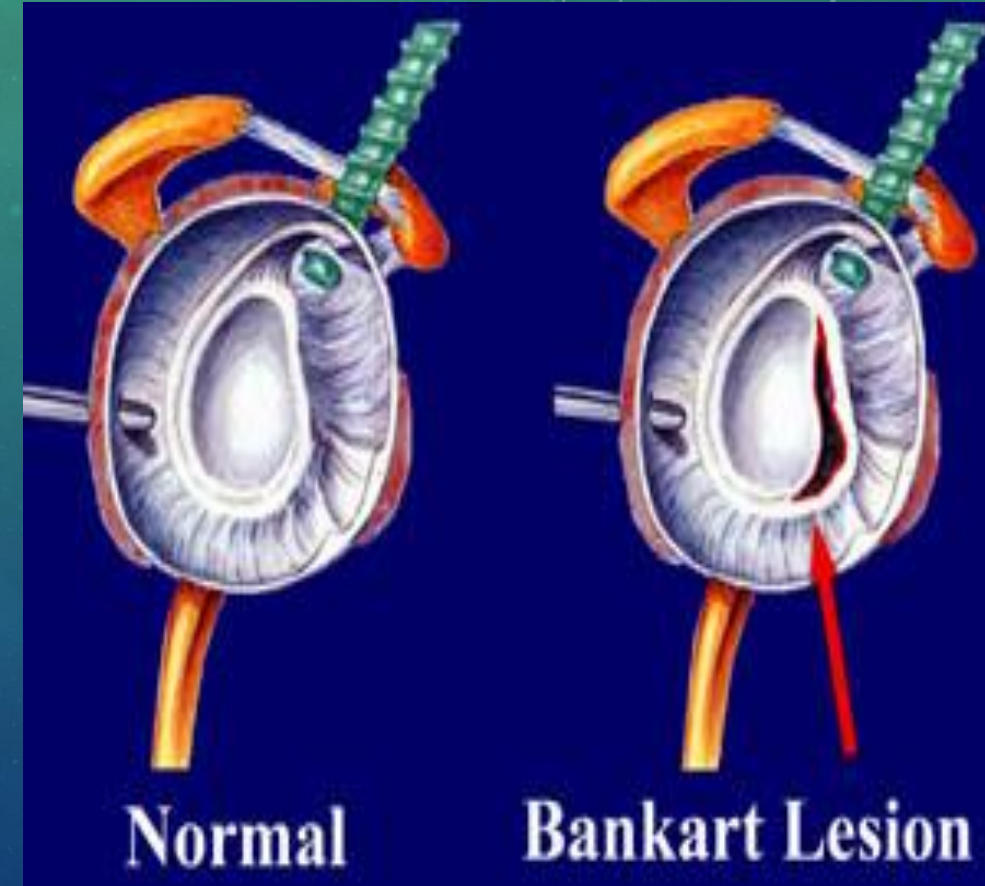
7) COMPLICATIONS

- **EARLY:**

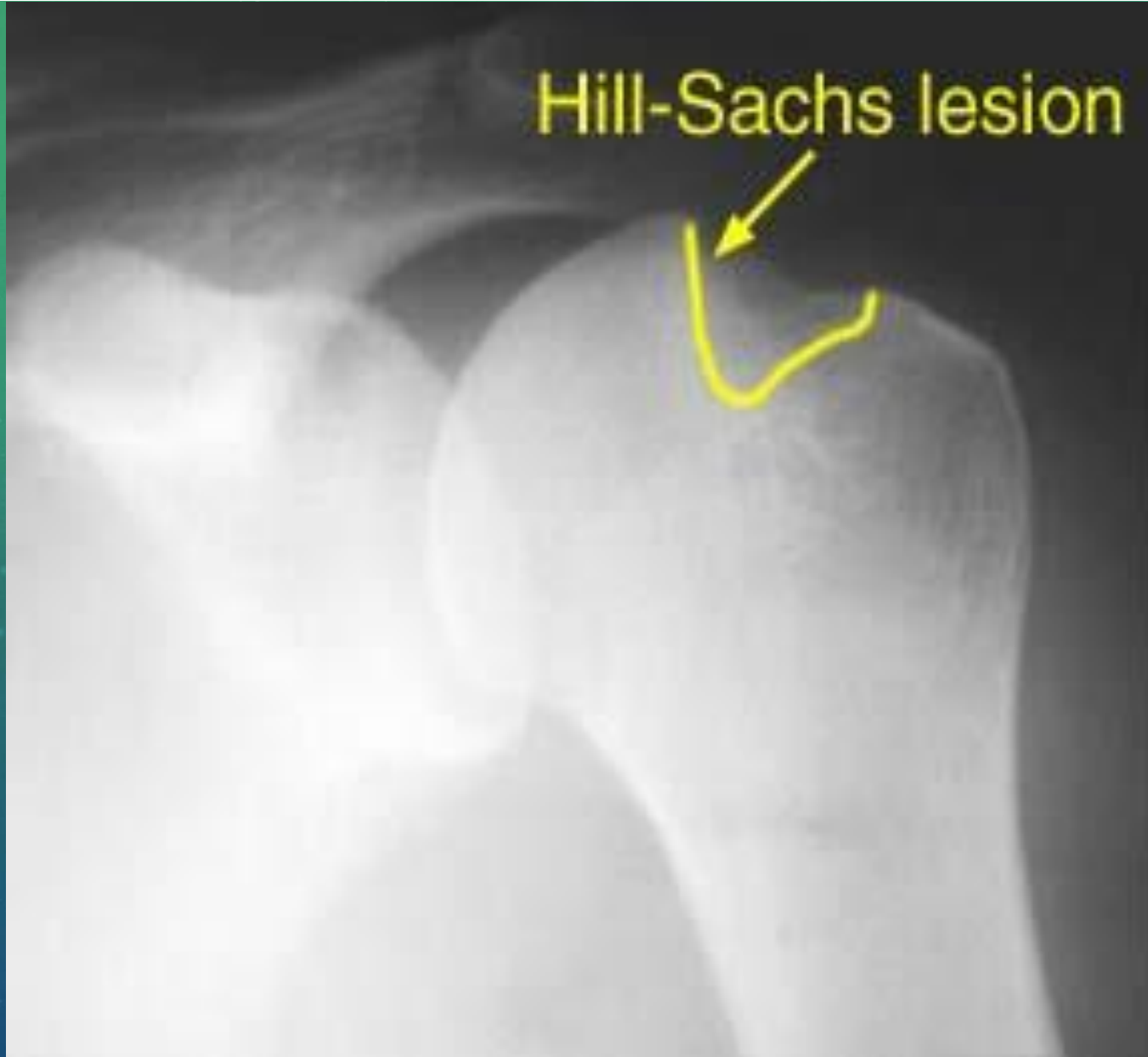- VASCULAR injuries: AXILLARY artery.
- NERVE injury: AXILLARY Nerve(Neuropraxia).
- Soft tissue injury: Rotator cuff injury.

- **LATE:**

- Shoulder stiffness.
- Un-reduced dislocation.
- Recurrent dislocation.
- Bankart Lesion (Antero-inferior lesion in glenoid labrum / glenoid rim)
- Hill-Sachs (Postero lateral defect in head of humerus)



Hill-Sachs lesion



SURGERIES FOR RECURRENT DISLOCATION

- **BANKART'S OPERATION:** Detached anterior structures are sutured to the rim of the glenoid cavity.
- **BRISTOW'S :** Transplantation of coracoid process with its attachments (short head of biceps & coraco-brachialis) to the anterior rim of glenoid through subscapularis muscle.
- **STAPLE CAPSULORRHAPHY OF DESTOT AND ROUX:** Bankart's lesion attached to labrum with staples.

- **PUTTI-PLATT'S OPERATION:** Double-Breasting of Subcapsularis tendon around the joint capsule.
- **MAGNUSON AND STACK :** Subcapsularis tendon and capsule is advanced laterally on the humerus

- **EDEN HYBINETTE** : Bone graft is placed against the anterior aspect of the neck of scapula and rim of glenoid cavity.
- **MCLAUGHLIN'S** : Tendon of subcapsularis is transplanted into the postero-lateral defect (Hill-sachs)

